

UNITED CONCORDIA[®]

August 2017 • V2 N2

FILLING YOU IN

Continuing
Education
2
CE CREDITS

Caring for Patients Affected by **Methamphetamine Use**

Lola Giusti, DDS; Jamie Jenkins MD, RDMS;
Mitchell A. Goodis, DDS; Carsen Bentley, DDS, MPH;
Christine E. Miller, MPH, RDH; and Alexander Faigen, DMD

PLUS

Continuing
Education
2
CE CREDITS

Dental Implant Maintenance

Sanda Moldovan, DDS, MS, CNS

Closing a Black Triangle with Composite Resin

Marcos A. Vargas, DDS

Many Technologies, One Restoration

David Burt, DDS

Plus:

A Word From Dr. Quinn Dufurrena



DEAR COLLEAGUES,

Welcome once again to United Concordia Dental's unique educational resource, *Filling You In*. This clinical e-newsletter selects and presents high level education, case studies, and other information relevant to today's oral healthcare professionals. From public healthcare issues to the latest in digital technology to patient home hygiene motivation, the practice of dentistry is expanding, necessitating continually updated resources.

This issue begins by asking what dentists can do to care for patients who abuse methamphetamine, as it can be extremely difficult to mitigate its destructive effects on oral health. These patients are often classified as "extreme caries risk." According to the authors, the goal of an integrated team of health professionals is to encourage recovery, improve re-socialization, decrease dental anxiety, and restore general and oral health. The authors propose a dual-purpose approach for treatment of individuals who are affected by this drug, with a strategy that combines caries arrest with oral hygiene improvement and disease prevention.

According to the author of our second article, the topic of dental implant maintenance is important but subject to confusion, due to a lack of protocol in the literature. When peri-implant disease develops, it is often difficult to treat, therefore practitioners should emphasize prevention. For example, the practitioner should be aware how the contours of the prosthesis can have a significant impact on the patient's ability to maintain good oral hygiene at home and keeping healthy peri-implant tissues. This article details a personalized approach to both home care and office hygiene visits, including the latest therapies.

Predictably resolving a patient's "black triangle" can be challenging. The first case report included in this issue presents a technique in which resin composite is used to augment the proximal contour of the adjacent teeth. In the second case, a single tooth implant restoration demonstrates how increasingly advanced digital technologies have improved efficiency, functionality, and esthetics.

I hope you find these articles stimulating and practical for your team. At United Concordia Dental, we're continually searching for new ways to update our nearly 7.5 million members on the advances, both sweeping and incremental, that are changing oral healthcare. Thank you for your interest and support.

Cordially,
Quinn Dufurrena, DDS, JD
Chief Dental Officer, United Concordia Dental

PUBLISHER

Dental Learning Systems, LLC

EDITOR

Catherine Paulhamus

SPECIAL PROJECTS MANAGER

Justin Romano

DESIGNER

Jennifer Barlow

CE COORDINATOR

Hilary Noden

CDEWorld and *Filling You In* are published by Dental Learning Systems.

Copyright ©2017 by Dental Learning Systems, LLC. All rights reserved under United States, International and Pan-American Copyright Conventions. No part of this publication may be reproduced, stored in a retrieval system or transmitted in any form or by any means without prior written permission from the publisher.

PHOTOCOPY PERMISSIONS POLICY: This publication is registered with Copyright Clearance Center (CCC), Inc., 222 Rosewood Drive, Danvers, MA 01923. Permission is granted for photocopying of specified articles provided the base fee is paid directly to CCC.

The views and opinions expressed in the articles appearing in this publication are those of the author(s) and do not necessarily reflect the views or opinions of the editors, the editorial board, or the publisher. As a matter of policy, the editors, the editorial board, the publisher, and the university affiliate do not endorse any products, medical techniques, or diagnoses, and publication of any material in this journal should not be construed as such an endorsement.

WARNING: Reading an article in CDEWorld and *Filling You In* does not necessarily qualify you to integrate new techniques or procedures into your practice. Dental Learning Systems, LLC expects its readers to rely on their judgment regarding their clinical expertise and recommends further education when necessary before trying to implement any new procedure.

Printed in the U.S.A.

CHIEF EXECUTIVE OFFICER

Daniel W. Perkins

CHIEF OPERATING OFFICER

Karen A. Auiler

PARTNER

Anthony A. Angelini



Dental Learning Systems, LLC
P.O. Box 510
Newtown, PA 18940
Phone - 267-291-1150

CONTENTS

2

Continuing Education

Caring for Patients Affected by Methamphetamine Use

Lola Giusti, DDS; Jamie Jenkins MD, RDMS; Mitchell A. Goodis, DDS;
Carsen Bentley, DDS, MPH; Christine E. Miller, MPH, RDH; and Alexander Faigen, DMD

10

Continuing Education

Dental Implant Maintenance

Sanda Moldovan, DDS, MS, CNS

19

Closing a Black Triangle with Resin Composites

Marcos A. Vargas, DDS

22

Many Technologies, One Restoration

David Burt, DDS



2



10



19

Caring for Patients Affected by Methamphetamine Use

Lola Giusti, DDS; Jamie Jenkins MD, RDMS; Mitchell A. Goodis, DDS; Carsen Bentley, DDS, MPH; Christine E. Miller, MPH, RDH; and Alexander Faigen, DMD

ABSTRACT

The use of methamphetamines is a significant public health concern not only in America but worldwide. The consequences of this drug's use are widespread, having major physiologic and psychological effects that are damaging to users' bodies and well-being. Meth use wreaks havoc on one's oral health, with the effects including demineralization of tooth surfaces, carious lesions, inflammation of the periodontium, and more. In addition to examining the neurotoxic effects that methamphetamines have on the brain, this article will discuss how dental professionals can approach treatment of individuals who are affected by this debilitating drug, utilizing a strategy that combines caries arrest with oral hygiene improvement and disease prevention. It will also review the use of various products to help establish a neutral oral pH and enhance enamel remineralization.

What is now considered an epidemic by some, the methamphetamine crisis in America has reached an all-time high, with more than 102,000 methamphetamine-related emergency department (ED) visits occurring in 2011 alone.¹ The

number of these visits has increased exceedingly since 1992, with the criminal justice system referring many of them.² The RAND Corporation has estimated the annual economic burden methamphetamine use places on society, including treatment, healthcare costs, disruption

LEARNING OBJECTIVES

- Discuss the public health concerns associated with the use of methamphetamines.
- Explain the major physiologic and psychological effects of methamphetamines and the neurotoxic impact on serotonin and dopamine neurons in the brain.
- Describe the effects meth use can have on the oral cavity and how dentists can approach treatment of meth users.

of family life, loss of productivity, criminal costs, and death, to be \$23.4 billion.³

Methamphetamine use has a long history (see sidebar).^{2,4,5} The crystallized form—crystal meth—provides a drug that is relatively easy to produce, inexpensive to purchase,

DISCLOSURE

Dr. Dickinson received an honorarium for the webinar program that was the basis of this article.

and longer lasting than its opioid counterparts. This washed, crystallized version of methamphetamine has a purity of up to 98%.⁶ Because crystal meth can be injected, swallowed, or smoked, is easy to transport, and is said to result in more intense “trips” that can last up to 12 hours, it is the drug of choice among methamphetamine users. Discontinuing its use is extremely difficult due to the withdrawal symptoms of anxiety, irritability, restlessness, fatigue, and dysphoria,⁷ forcing users to partake in what is known as “tweaking.” “Tweakers” reinforce their “high” by using the drug for periods of time ranging from days to weeks, allowing themselves to defer facing withdrawal. The eventual result is a terrible withdrawal consisting of a restless, sometimes unarousable, sleep with sweats followed by sores, itching, decayed teeth, and nightmarish feelings of bugs crawling on their skin.

Long-term users of crystal meth have said that they are unable to remember large periods of their life, even forgetting where they once lived. Some have long-lasting psychiatric problems and need to take such drugs as Prozac every day just to feel better. Chronic abuse can cause psychotic and violent behavior characterized by intense paranoia, visual and auditory hallucinations, and out-of-control rages, even in those who have been abstinent for years.⁶

In light of concerns regarding the drug’s ability to cause long-term neurological damage and cognitive impairment, numerous studies have been conducted that have researched the effects of methamphetamines. Some studies have looked at the biochemical effects of methamphetamines, while others have examined differences in brain mass and volumes in users compared to non-users.⁵ In addition to discussing the public health concern caused by methamphetamine use, this article will describe the major physiologic and psychological effects of meth as noted in both animal and human studies and will examine the neurotoxic effects that meth has on serotonin and dopamine neurons in the brain. It will describe the factors involved in the neurophysiology of meth and discuss factors relating to its strong addictive and neurotoxic potential. Additionally, it will present ways in which dentists can treat this patient population.

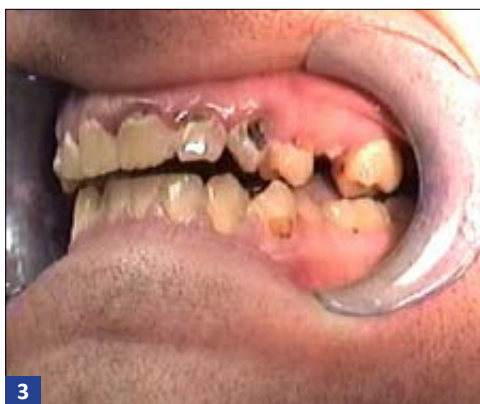
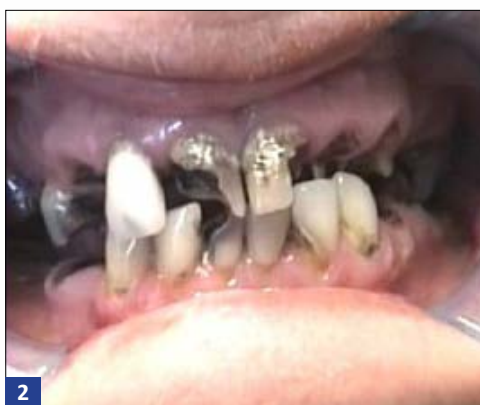
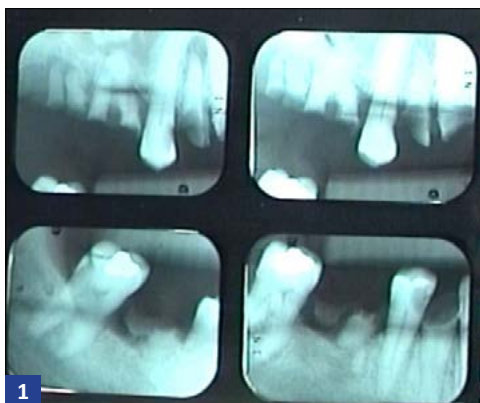Fig 1. Radiographs showing an example of “meth mouth.” **Fig 2.** Gross oral destruction was the result of more than 20 years of meth use in this 41-year-old woman. **Fig 3.** After 5 years of meth use in a 22-year-old male patient, cervical decay and coronal fractures were evident.

Public Health Concern

The use of methamphetamines is a public health concern not only in America but the entire world, with more than 35 million people regularly using meth worldwide.⁸ The United States is seventh on the list of the highest

prevalence of amphetamine-type stimulant users, most of whom use meth.⁹ Moreover, the epidemic is spreading; while the numbers of users have begun to stabilize in the western US states, the eastern US states are just starting to experience the problem.

With increased use comes a strong burden on the population at large and state governments. As discussed above, longer-term use can result in substantial cognitive, social, and psychological deficits as well as neurotoxicity. Though numerous studies have examined the effects of meth in these areas, treatments for these conditions have, at best, had a minimal impact. Those who abuse meth are also at risk of sexually transmitted and bloodborne diseases as they become compulsive and obsessive with sexual behaviors.⁹⁻¹¹ There is also an increased risk of other health and social consequences.¹² As Hawaii and California have experienced, patients who were positive for meth were more likely to have intentional self-inflicted injuries, suicide,¹⁰ or intentional assaults and were also more likely to end up in prison.⁹

The National Drug Intelligence Center has even put out a warning about the volatility of the vapors used in the manufacturing of the drug as the number of burn patients from meth lab explosions has increased. Consequently, the number of patients admitted to burn centers for severe burns has also risen, with a mean cost to the hospital of \$77,580 per patient as meth users rarely have the means to pay for their treatment.⁹ Additionally, children (including those exposed in utero) exposed to these environments (ie, at-home meth labs) have been found to tend to have developmental delays.¹³

Another issue associated with meth production is waste disposal. State governments have a difficult time disposing of the waste, as one lab can manufacture up to 10 pounds of meth in a 24-hour period and each pound of meth creates six pounds of hazardous waste that must be disposed.⁸ This is a significant economic burden and a problem that needs to be addressed because research alone into the effects of meth cannot change the situation.

Physiology of Meth

Meth is an indirectly acting sympathomimetic that precipitates a massive, sustained release of

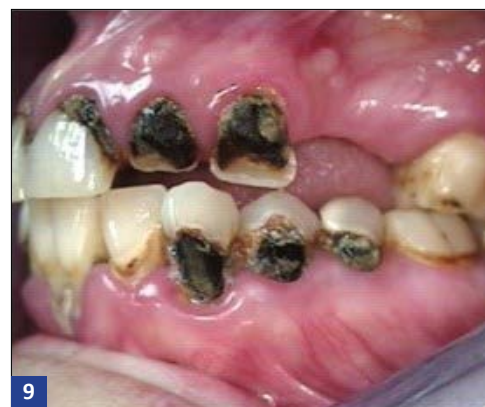
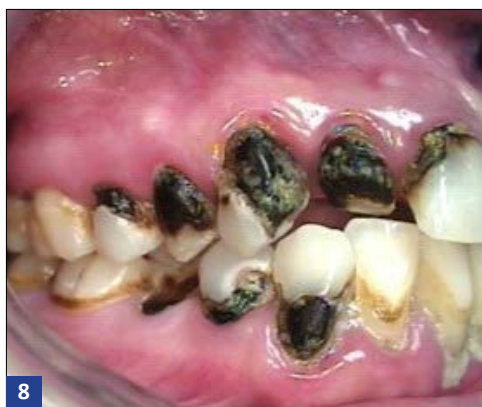
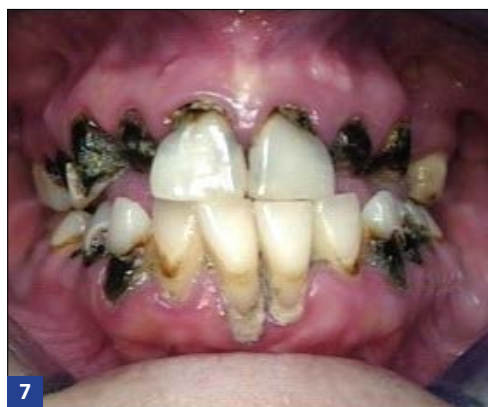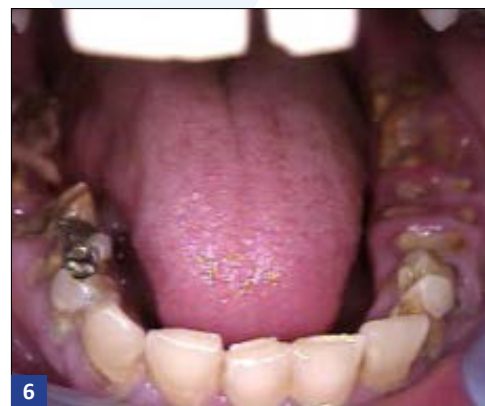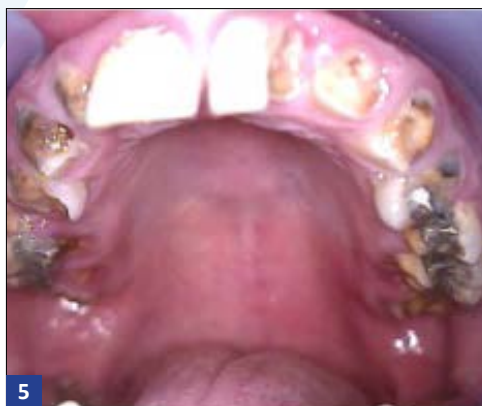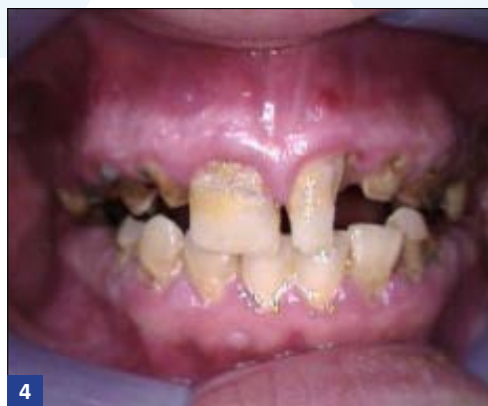Fig 4 through Fig 6. Patient's oral condition after 6 years of meth use. **Fig 7 through Fig 9.** This young patient's only prosthetic option was extraction of all remaining teeth and subsequent placement of complete dentures.

dopamine in the brain, causing the “high” that users pursue.¹⁴ Meth's activity differs as a function of location in the brain. There are three major dopaminergic systems: the nigrostriatal, mesolimbic, and mesocortical systems. In the striatum, meth stimulates the release of dopamine via five mechanisms. It increases the release of dopamine from storage vesicles; inhibits monoamine oxidase, the enzyme responsible for breaking down dopamine; blocks the reuptake at the synaptic cleft; decreases the expression of dopamine transporters at the cell surfaces; and increases the expression of tyrosine hydroxylase (which allows the conversion of tyrosine into dopamine).⁸

In the nigrostriatal pathway, the released dopamine stimulates the D1 receptors on the gamma amino butyric acid (GABA) neurons causing an increased release of GABA, the main inhibitory neurotransmitter in the brain. GABA then stimulates the GABA (a) receptors on the postsynaptic neurons, resulting in the

inhibition of the nigrothalamic projections. Because these projections are also inhibitory, their silence consequently allows the stimulation of the thalamocortical projections. These projections then increase their release of glutamate, the major stimulatory neurotransmitter in the brain.¹⁵ Glutamate stimulates the striatum and, together with the increased release of dopamine, can lead to oxidative and excitatory neurotoxic damage¹⁵ as well as the positive symptoms in meth addicts that are similar to those seen in schizophrenics (euphoria, hallucinations, strange or unusual beliefs and alertness, increased libido, and decreased appetite^{8,9}).

As a central acting stimulant, meth exerts its effect on almost every organ, from the heart and adrenal glands to the lungs and kidneys. Briefly, meth can cause chest pain, hypertension, and myocardial infarctions, as well as dyspnea and wheezing. Its most severe effects are strokes, pulmonary edema, necrotizing angitis

with arterial aneurysms, and sacculations in the kidney, liver, and pancreas. Notably, meth (and also Ecstasy) reduces both salivary quality and quantity, resulting in xerostomia and Sicca syndrome; this is due possibly to stimulation in the brain of alpha2-sympathetic adrenoreceptors, inhibiting salivary secretion.¹⁶

Often, the most visually striking manifestation of long-term meth use—known as “meth mouth”—is caused by the lack of saliva combined with an increase in soda drinking and extremely poor oral hygiene. This typically leads to meth abusers experiencing a large amount of caries. Decay begins with occlusal and facial caries and progresses rapidly, decaying to the bone level and often leaving only roots (Figure 1 through Figure 3).¹⁶

Examples of Oral Destruction

The patient shown in Figure 4 through Figure 6 was a meth user for 6 years. He had a stroke at age 22. After recovering from the stroke

and stabilization of his circulatory system was achieved, and once he quit using meth, he strongly desired to apply for a job and wished to improve his dental appearance. He opted to have all of his teeth extracted, as complete dentures were his only treatment option because there were no adequate abutment teeth remaining for placement of removable partial dentures.

In Figure 7 through Figure 9, the young woman shown had many adverse childhood experiences and was given methamphetamine by an adult when she was 14 years old. She also had her first child at that age, and then had three more children while addicted to meth, though she was only able to retain custody of one of her children. In addition to alcohol, she used meth for 15 years. Her only prosthetic option was extraction of all of her remaining teeth and subsequent placement of complete dentures.

The patient in Figure 10 through Figure 12 was pregnant when she presented for dental treatment. The pregnancy was unplanned and she had had a lack of prenatal care. Continuing meth use during the pregnancy resulted in a positive toxic baby. She stated that she had just stopped using meth and had entered a rehabilitation facility a few days before. She was brought to the author's clinic with a toothache. Note that as seen in these images, extreme accumulation of plaque, lack of oral hygiene, and severely decayed and missing teeth are classic manifestations in meth users.

What Dentists Can Do to Help

Caring for patients who abuse methamphetamine is challenging. When meth use is ongoing it is extremely difficult to mitigate the dentally destructive effects of this substance. Early interventions will have the best outcomes in terms of saving teeth. Because of the intense xerostomia associated with methamphetamine, patients who use it are automatically classified as "extreme caries risk."¹⁷ The authors propose a dual-purpose approach: caries arrest combined with oral hygiene improvement and prevention. The former may be accomplished with the use of silver diamine fluoride (SDF).

SDF is an antimicrobial liquid and desensitizing agent used to treat dentin hypersensitivity. It is available in the United States as a

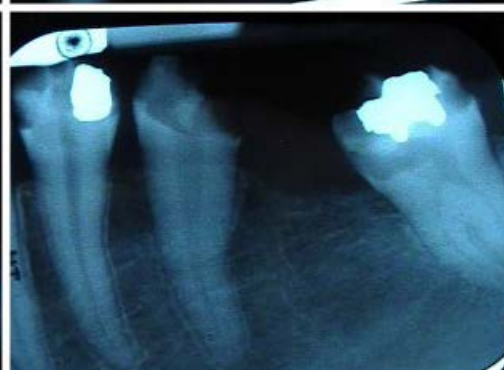
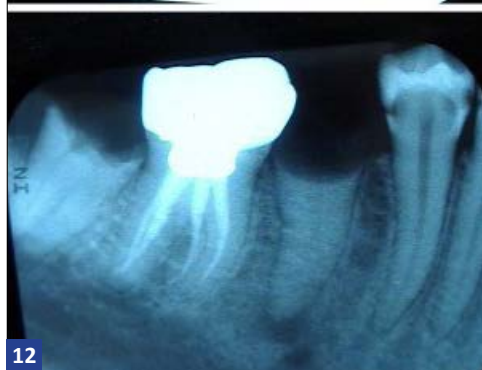
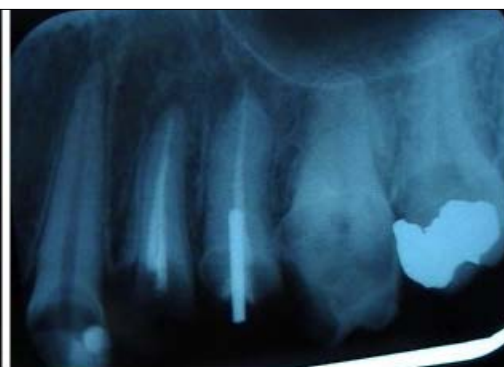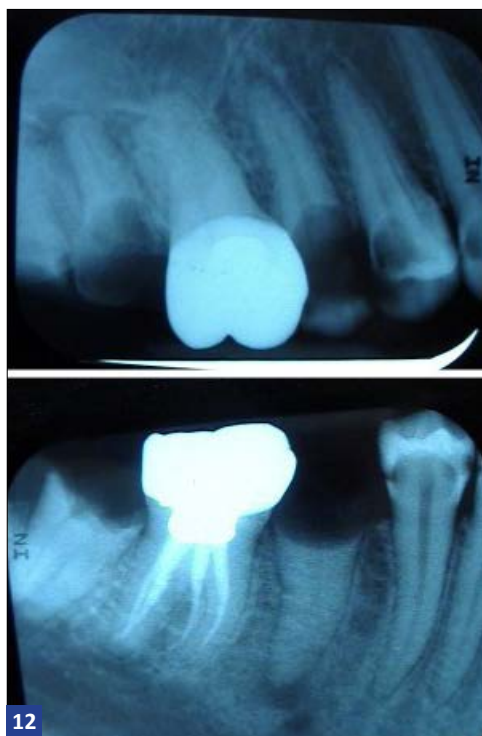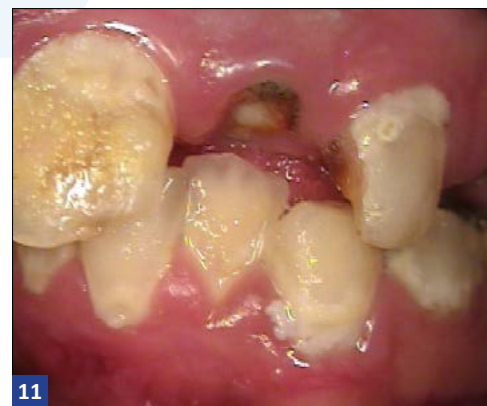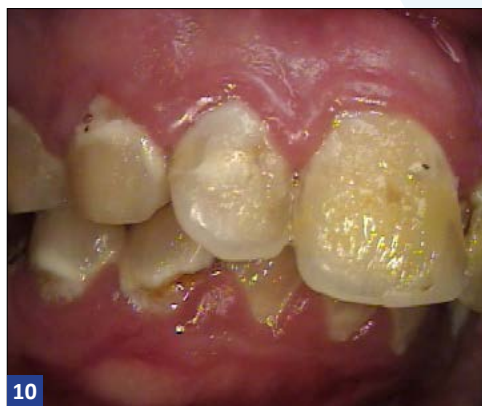Fig 10. Accumulation of soft plaque is typical of oral hygiene neglect associated with the use of methamphetamine. **Fig 11.** Note demineralization of smooth surfaces, carious lesions at the gingival margins, and associated inflammation of the periodontium. **Fig 12.** Radiographs of patient in Fig 10 and Fig 11 illustrating nonrestorability of the dentition.

38% solution. Like other desensitizing agents being used off-label as best practice for preventing incident dental caries, SDF offers the additional promise of arresting extant dental caries.¹⁸⁻²⁰ SDF accomplishes this by being bactericidal and forming an acid-resistant protective layer on the tooth. The silver in SDF kills the cariogenic biofilm bacteria, and the fluoride inhibits demineralization and promotes

remineralization of the dental hard tissue by converting hydroxyapatite to fluorapatite.^{19,20} As a result of applying SDF to a tooth surface, black staining precipitates as silver salts (silver phosphate), which become embedded in the active decay lesion, adjacent biofilm, and/or soft tissue. This light-sensitive compound will react to turn the decay from soft and brown to hard and black, and it may then be restored

Caring for Patients Affected by Methamphetamine Use

TABLE 1. **CARIES RISK PROTOCOLS FOR PATIENTS USING METHAMPHETAMINES**²⁶

<p>RISK CATEGORY Extreme (High risk plus dry mouth or special needs) (1 or more cavitated lesions plus hyposalivation is considered extreme risk)</p>	<p>XYLITOL 6+: 6-10 grams per day <6: Xylitol wipes and substitute for sweet treats or when unable to brush Caregiver: 2 sticks of gum or 2 mints 4 times per day</p>
<p>RECARE EXAMINATION 6+: every 3 months <6: every 1-3 months</p>	<p>ANTIMICROBIALS (IE, CHLORHEXIDINE) 6+: 0.12% Chlorhexidine gluconate 10-ml rinse for 1 minute per day for 1 week each month Antimicrobial therapy should be done in conjunction with restorative treatment <6: Recommend for caregiver</p>
<p>RADIOGRAPHS 6+: BMX every 6 months <6: Anterior PAX and BMX every 6-12 months</p>	<p>CALCIUM PHOSPHATE 6+: Apply paste several times daily <6: Brush with smear (0-2 years) or pea size (3-6 years) 1 time per day, leave on at bedtime</p>
<p>SALIVA TESTING 6+ and <6: required at baseline and recare examinations</p>	<p>SEALANTS (RESIN-BASED AND GLASS IONOMERS) 6+: Recommended <6: Fluoride-releasing sealants or glass ionomers on deep pits and fissures</p>
<p>FLUORIDE 6+ Home: 1.1% NaF toothpaste 1-2 times per day and 0.05% NaF rinse when mouth feels dry, especially after eating or snacking 6+ In-office: Initially 1-3 applications fluoride varnish and at recare appointment <6 Home: OTC toothpaste 2 times per day <6 In-office: fluoride varnish at initial visit and recare Caregiver: OTC NaF rinse</p>	<p>pH NEUTRALIZING 6+: Acid neutralizing rinses/gums/mints if mouth feels dry, after breakfast, snacking, and at bedtime <6: No</p>

Adapted from Jenson L, Budenz AW, Featherstone JD, et al. *J Calif Dent Assoc.* 2007;35(10):714-723. Reprinted with permission from the California Dental Association, copyright October 2007.

definitively as needed. The staining effect on the biofilm and soft tissue is transient and may be polished away or allowed to naturally desquamate (Figure 13 through Figure 15). Healthy tooth structure will remain unchanged and will not stain black.

Dental professionals are currently using SDF to help slow or stop the caries process on accessible tooth surfaces until the patient is able to be safely treated with conventional dental care to restore esthetics and function. SDF protocol is a promising, evidence-informed, science-based practice that is particularly helpful for a variety of situations.¹⁷ These include very young children who cannot be treated in a traditional dental office setting and may be waiting for a hospital dental appointment; patients with extreme caries risk due to xerostomia; patients with complex behavioral or medical comorbidities that make conventional dental treatment difficult; patients with carious

lesions affecting the entire permanent dentition, making it unfeasible to treat in a timely manner; carious lesions on surfaces that are difficult to treat clinically due to accessibility; and use in population-based low-intensity dental disease prevention strategies by street outreach workers in lieu of access to dental care.²¹ SDF can also be used to safely delay extensive treatment to allow for primary prevention practices to be adopted or to allow time for other, more urgent life circumstances to be addressed such as substance misuse, rehabilitation, or homelessness.

Effective prevention counseling and treatment with current meth users or methadone maintenance therapy (MMT) clients requires use of an interprofessional model of health-care delivery. Prevention requires a holistic approach and competent communication.²² Holistic prevention takes into consideration the related health and economic issues

MMT clients face, such as poor self-esteem, depression, and often lower socioeconomic status. MMT clients tend to also present undernourished and with anxiety disorders, diabetes, asthma, and poor general health.²³

People in recovery, ie, current methamphetamine users or MMT patients, exhibit similar characteristics when presenting to health professionals. Often these individuals present with behavioral and psychological challenges that create barriers to following prevention recommendations and accessing oral healthcare.²⁴ Charnock et al showed that while almost 60% of nondrug users made use of dental services regularly, only 29% of drug users did so.²⁵

Specific prevention services, health counseling, and product recommendations by dental professionals are based upon the risk assessment.

Xerostomia and high caries risk are com-

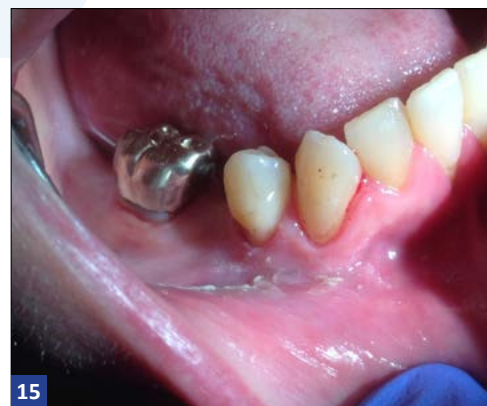
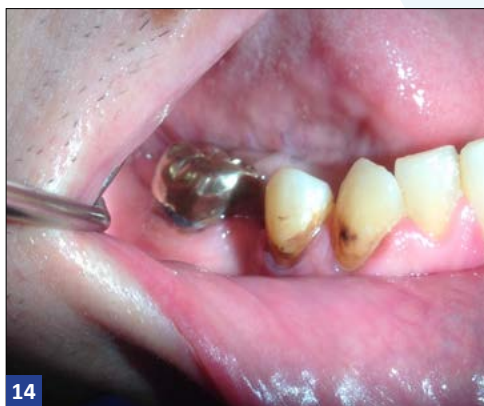
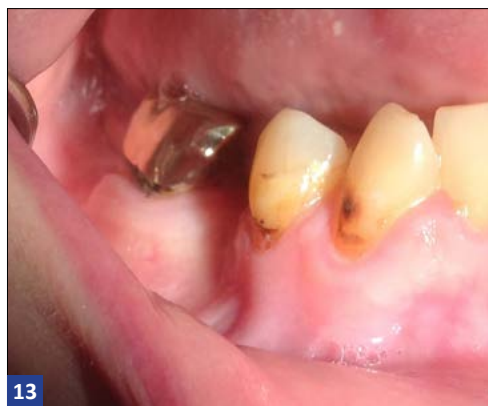Fig 13. Smooth-surface caries in a methamphetamine-using patient. **Fig 14.** Appearance of lesions after one application of SDF. **Fig 15.** Carious lesions restored with composite resin. Note satisfactory masking of dark staining after SDF treatment.

mon debilitating oral findings of meth users and MMT clients. A primary prevention goal is to establish and maintain a neutral pH of the oral cavity. Use of a baking soda (sodium bicarbonate) water rinse is an economical, readily available method to achieve a non-acidic oral environment. To stimulate saliva, sugar-free chewing gum containing xylitol can be used.

The cost and availability of prevention products to establish a neutral oral pH and enhance enamel remineralization varies. Examples of prevention products are PreviDent® (Colgate Professional, www.colgate-professional.com), Fluoride Varnish™ (3M ESPE, www.3m.com), MI Paste™ (GC America Inc., www.mi-paste.com), and CTx4 Treatment Rinse (CariFree, www.carifree.com). For direct preventive dental services, a reduced length of appointment time of 20 to 30 minutes for a dental cleaning and avoiding deep scaling during recovery withdrawal periods have been recommended.²⁴ In addition to brushing three times daily and flossing twice daily, a variety of products may be implemented immediately for patients with methamphetamine-associated xerostomia. Some products include ACT® Dry Mouth mouthwash, lozenges, and toothpaste (Chattem Inc., www.ctoralcare.com), Xerostom® (Biocosmetics Laboratories, www.biocosmetics.es), Xylitol gum (Epic Dental LLC, www.epicdental.com), and Dry Mouth Relief (Colgate Professional).

The essential goal of an integrated team of health professionals for a meth user or

MMT client is to encourage recovery, improve re-socialization, decrease dental anxiety, and restore general and oral health. Hygiene improvement and preventive den-

tistry utilizes a caries risk assessment. Patients using methamphetamines fall into the extreme risk category and may be cared for by adopting protocols appropriate for that

THE HISTORY OF METHAMPHETAMINE—FROM ASTHMA TREATMENT TO CRYSTAL METH

Methamphetamine (meth) was first synthesized in Japan in 1893. Primarily, the drug was placed in inhalers for treating rhinitis and asthma. Subsequently, it was used by American, English, and German troops during World War II as a stimulant to maintain wakefulness and increase energy and suppress appetite. Shortly after the war, the Japanese military released the remainder of its drug supply to the civilian market, causing Japan's first methamphetamine crisis. Today, Japan is the country with the highest use per capita in the world.¹

The news of the anorectic and stimulant effects of meth soon spread to American communities, leading to a surge in its use. In the late 1950s, the US government enacted Federal statutes in an attempt to control its spread. The success was minimal as the drug became increasingly popular among students, athletes, and shift workers.² In the 1960s, Life magazine addressed the growing problem with this class of drugs, publishing an article on the effects of using amphetamines (of which meth is a subgroup) as diet drugs.³ In 1970, the Controlled Substances Act was passed, which again attempted to halt the popularity and use of meth. Placing strict controls in effect, this act managed to decrease the manufacture of the drug within US borders, unknowingly encouraging production to take place underground and outside the United States.

Drug trafficking organizations in Mexico and Asia, as well as the Mafia, stood at the ready. Legislation had failed to control the ever-growing demand for meth, leading to "mom and pop" meth labs springing up in California and Hawaii during the late 1990s. As its popularity grew, the use of the drug changed from a short-term stimulant helpful in dieting and improving attention spans to a longer-lasting and more intense stimulation sought in recreational drug use. The crystallized form of methamphetamine—crystal meth—filled this niche, providing a drug that was relatively easy to produce, inexpensive to purchase, and longer lasting than its opioid counterparts.

Caring for Patients Affected by Methamphetamine Use

group. Table 1 outlines caries risk protocols for patients in this category.²⁶

Working Together

The interprofessional team model is essential to address prevention and oral health for meth users and MMT clients. To counteract the potential cariogenic effect of the sucrose syrup, methadone can be prepared in a sugar-free solution.²⁷ Practical prevention counseling and preventive services delivered by nurses, physicians, nutritionists, and behavioral and social service professionals complement the services of dentists, dental therapists, and dental hygienists.

ABOUT THE AUTHORS

Lola Giusti, DDS

Assistant Professor, Department of Removable Prosthodontics, University of the Pacific, Dugoni School of Dentistry, San Francisco, California; Private Practice, San Francisco, California

Jamie Jenkins MD, RDMS

Education Director, St. Clare Hospital, Lakewood, Washington; TeamHealth, Emergency Medicine Attending Physician

Mitchell A. Goodis, DDS

Private Practice, El Dorado, California

Carsen Bentley, DDS, MPH

Instructor, Department of Dental Practice and Community Programs, University of the Pacific, Dugoni School of Dentistry, San Francisco, California

Christine E. Miller, MPH, RDH

Associate Professor, Director of Community Health Programs, Department of Dental Practice and Community Programs, University of the Pacific, Dugoni School of Dentistry, San Francisco, California

Alexander Faigen, DMD

Dental Resident, VA Pittsburgh Healthcare System, Pittsburgh, Pennsylvania

REFERENCES

1. Emergency Department Visits Involving Methamphetamine: 2007-2011. Substance Abuse and Mental Health Services Administration (SAMHSA) website. June 19, 2014. www.samhsa.gov/data/sites/default/files/DAWN_SR167_EDVisits-Meth_06-12-14/DAWN-SR167-EDVisitsMeth-2014.htm. Accessed May 1, 2017.
2. Lineberry TW, Bostwick JM. Methamphetamine abuse: a perfect storm of complications. *Mayo Clin Proc.* 2006;81(1):77-84.
3. Nicosia N, Pacula RL, Kilmer B, et al. *The Economic Cost of Methamphetamine Use in the United States*, 2005. Santa Monica, CA: RAND Corporation, Drug Policy Research Center; 2009.
4. eMedicine Clinical Knowledge Base, Institutional Edition; Toxicity, Methamphetamine. www.emedicine.com.
5. Chang L, Cloak C, Patterson K, et al. Enlarged striatum in abstinent methamphetamine abusers: a possible compensatory response. *Biol Psychiatry.* 2005;57(9):967-974.
6. National Drug Intelligence Center. Information Bulletin: Crystal Methamphetamine. August 2002. www.justice.gov/archive/ndic/pubs1/1837/index.htm. Accessed May 1, 2017.
7. Petit A, Karila L, Chalmin F, Lejoyeux M. Methamphetamine addiction: a review of the literature. *J Addict Res Ther.* 2012;S1:006. doi:10.4172/2155-6105.S1-006.
8. Barr AM, Panenka WJ, MacEwan GW, et al. The need for speed: an update on methamphetamine addiction. *J Psychiatry Neurosci.* 2006;31(5):301-313.
9. Maxwell JC. Emerging research on methamphetamine. *Curr Opin Psychiatry.* 2005;18(3):235-242.
10. Chana G, Everall IP, Crews L, et al. Cognitive deficits and degeneration of interneurons in HIV+ methamphetamine users. *Neurology.* 2006;67(8):1486-1489.
11. Worth H, Rawstorne P. Crystallizing the HIV epidemic: methamphetamine, unsafe sex, and gay diseases of the will. *Arch Sex Behav.* 2005;34(5):483-486.
12. Callor WB, Petersen E, Gray D, et al. Preliminary findings on noncompliance with psychotropic medication and prevalence of methamphetamine intoxication associated with suicide completion. *Crisis.* 2005;26(2):78-84.
13. Smith LM, Chang L, Yonekura ML, et al. Brain proton magnetic resonance spectroscopy in children exposed to methamphetamine in utero. *Neurology.*

2001;57(2):255-260.

14. Ernst T, Chang L, Leonido-Yee M, Speck O. Evidence for long-term neurotoxicity associated with methamphetamine abuse: a 1H MRS study. *Neurology.* 2000;54(6):1344-1349.
15. Mark KA, Soghomonian JJ, Yamamoto BK. High-dose methamphetamine acutely activates the striatonigral pathway to increase striatal glutamate and mediate long-term dopamine toxicity. *J Neurosci.* 2004;24(50):11449-11456.
16. Shaner JW, Kimmes N, Saini T, Edwards P. "Meth mouth": rampant caries in methamphetamine abusers. *AIDS Patient Care STDS.* 2006;20(3):146-150.
17. Horst JA, Ellenikiotis H, Milgrom PL. UCSF protocol for caries arrest using silver diamine fluoride: rationale, indications, and consent. *J Calif Dent Assoc.* 2016;44(1):16-28.
18. Llodra JC, Rodriguez A, Ferrer B, et al. Efficacy of silver diamine fluoride for caries reduction in primary teeth and first permanent molars of schoolchildren: 36-month clinical trial. *J Dent Res.* 2005;84(8):721-724.
19. Rosenblatt A, Stamford TC, Niederman R. Silver diamine fluoride: a caries "silver-fluoride bullet." *J Dent Res.* 2009;88(2):116-125.
20. Featherstone JDB, Horst JA. Fresh approach to caries arrest in adults. *Decisions in Dentistry.* 2015;1(1):36-44.
21. Brown C, Krishnan S, Hursh K, et al. Dental disease prevalence among methamphetamine and heroin users in an urban setting: a pilot study. *J Am Dent Assoc.* 2012;143(9):992-1001.
22. Robinson PG, Acquah S, Gibson B. Drug users: oral health-related attitudes and behaviours. *Br Dent J.* 2005;198(4):219-224.
23. Titsas A, Ferguson MM. Impact of opioid use on dentistry. *Aust Dent J.* 2002;47(2):94-98.
24. Brondani M, Park PE. Methadone and oral health—a brief review. *J Dent Hyg.* 2011;85(2):92-98.
25. Charnock S, Owen S, Brookes V, Williams M. A community based programme to improve access to dental services for drug users. *Br Dent J.* 2004;196(7):385-388.
26. Jenson L, Budenz AW, Featherstone JD, et al. Clinical protocols for caries management by risk assessment. *J Calif Dent Assoc.* 2007;35(10):714-723.
27. Sheedy JJ. Methadone and caries. Case reports. *Aust Dent J.* 1996;41(6):367-369.

CONTINUING EDUCATION 1

QUIZ

Continuing
Education

2

CE CREDITS

Caring for Patients Affected by Methamphetamine Use

Lola Giusti, DDS; Jamie Jenkins MD, RDMS; Mitchell A. Goodis, DDS; Carsen Bentley, DDS, MPH; Christine E. Miller, MPH, RDH; and Alexander Faigen, DMD

This article provides 2 hours of CE credit from Dental Learning Systems, LLC. Log on to cdeworld.com/go/ucci-ce7 to take the CE quiz for a fee of \$18. You may also phone your answers in to 877-423-4471 or fax them to (215) 504-1502. Be sure to include your name, address, telephone number, and last 4 digits of your Social Security number.

[CLICK HERE TO TAKE THE QUIZ ONLINE](#)

- Crystal meth provides a drug that is:**
 - relatively easy to produce.
 - inexpensive to purchase.
 - longer lasting than its opioid counterparts.
 - all of the above.
- Crystal meth is a washed, crystallized version of methamphetamine and has a purity of up to:**
 - 8%.
 - 38%.
 - 68%.
 - 98%.
- Crystal meth can be:**
 - injected.
 - swallowed.
 - smoked.
 - All of the above
- "Tweakers" reinforce their "high" by using the drug for periods of time ranging from days to weeks:**
 - which increases the ultimate high two-fold.
 - which increases the ultimate high four-fold.
 - which increases the ultimate high an amazing ten-fold.
 - allowing themselves to defer facing withdrawal.
- Meth is an indirectly acting sympathomimetic that precipitates a massive, sustained release of what in the brain?**
 - dopamine
 - glutamate
 - oxytocin
 - endorphin
- Often, the most visually striking manifestation of long-term meth use—known as "meth mouth"—is caused by:**
 - the lack of saliva.
 - an increase in soda drinking.
 - extremely poor oral hygiene.
 - All of the above
- Because of the intense xerostomia associated with methamphetamine, patients who use it are automatically classified as:**
 - "positive caries risk."
 - "mild caries risk."
 - "moderate caries risk."
 - "extreme caries risk."
- SDF is an antimicrobial liquid and desensitizing agent used to treat:**
 - excessive cementum loss.
 - enamel erosion.
 - dentin hypersensitivity.
 - periodontal pocketing.
- The silver in SDF:**
 - kills the cariogenic biofilm bacteria.
 - removes toxins often found in the periodontal sulcus.
 - lowers salivary pH.
 - increases salivary pH.
- What is essential to address prevention and oral health for meth users and MMT clients?**
 - topical fluoride
 - silver diamine fluoride
 - shortened recall schedule
 - the interprofessional team model

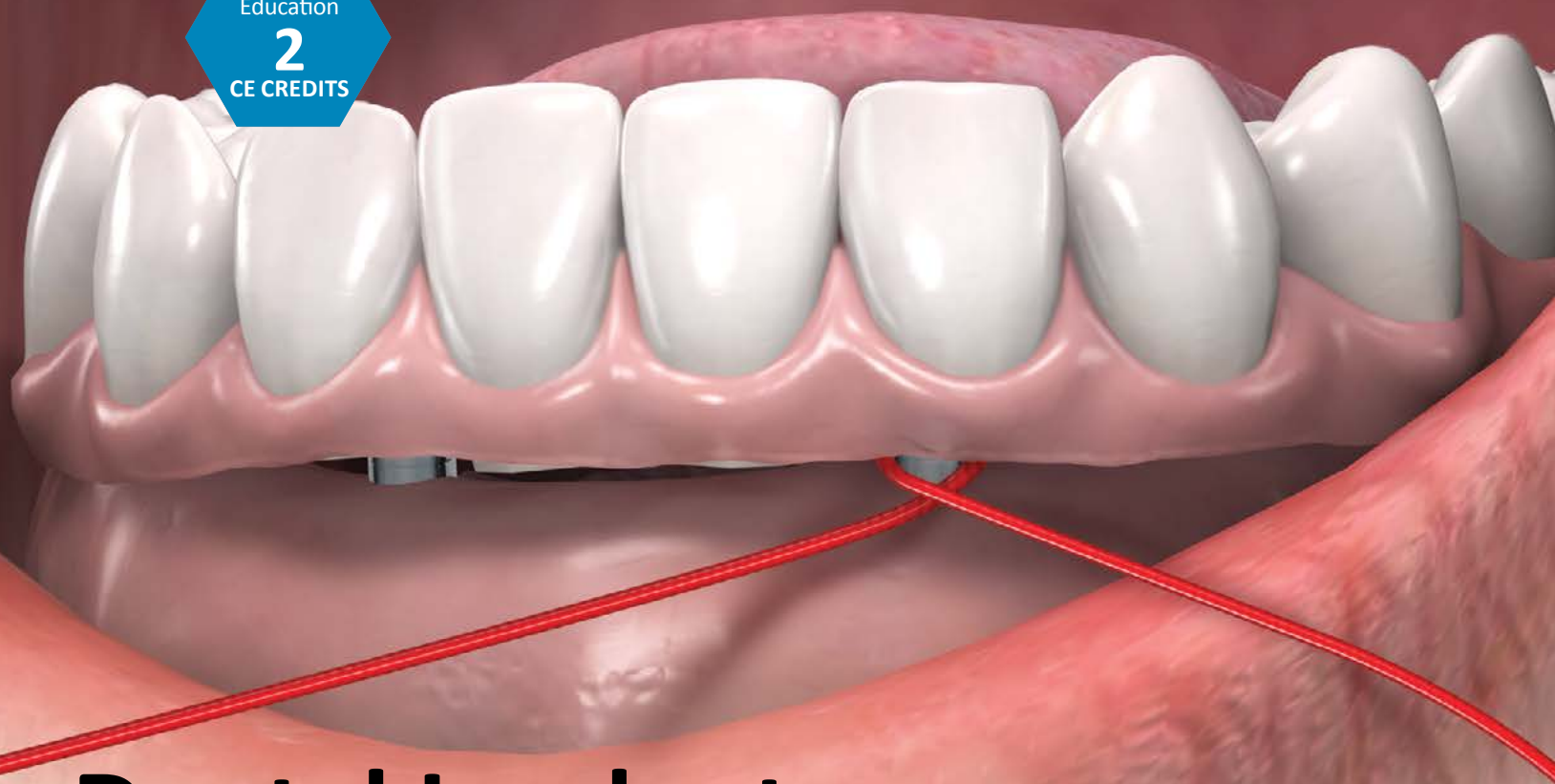
Course is valid from 7/1/2017 to 7/31/2020. Participants must attain a score of 70% on each quiz to receive credit. Participants receiving a failing grade on any exam will be notified and permitted to take one re-examination. Participants will receive an annual report documenting their accumulated credits, and are urged to contact their own state registry boards for special CE requirements.

ADA CERP® | Continuing Education
Recognition Program

Dental Learning Systems, LLC, is an ADA CERP Recognized Provider. ADA CERP is a service of the American Dental Association to assist dental professionals in identifying quality providers of continuing dental education. ADA CERP does not approve or endorse individual courses or instructors, nor does it imply acceptance of credit hours by boards of dentistry. Concerns or complaints about a CE provider may be directed to the provider or to ADA CERP at www.ada.org/cerp.



Approved PACE Program
Provider FAGD/MAGD Credit
Approval does not imply
acceptance by a state or
provincial board of dentistry or
AGD endorsement
1/1/2017 to 12/31/2022.
Provider #: 209722.



Dental Implant Maintenance

Sanda Moldovan, DDS, MS, CNS

ABSTRACT

Patients and their dentists need to understand that implants are not the same as teeth—particularly in how they attach to bone and soft tissue—and, therefore, they must be maintained differently and monitored carefully, both at home by the patient and during hygiene visits. In all cases, dental implant maintenance protocol should be personalized for the needs of the individual patient, and clinical implant parameters should be documented on a regular basis. Most of all, every effort should be made to prevent progression of peri-implant mucositis to peri-implantitis, which is unpredictable and can lead to failure of the dental implant.

LEARNING OBJECTIVES

- Understand the difference between teeth and implants in terms of their attachment to the bone and soft tissue.
- Describe the components of a personalized home care program.
- Describe a recommended hygiene visit protocol for dental implants.

DISCLOSURE

Dr. Moldovan received an honorarium for the preparation of this manuscript.

As a periodontist whose practice is largely focused on dental implant therapy, the author believes the topic of dental implant maintenance is important but subject to confusion due to a lack of protocol in the literature. The fact is, implants are not like teeth and, therefore, must be maintained differently. Further, because when peri-implant disease develops, it is so unpredictable and difficult to treat, practitioners should make every effort to prevent its occurrence if possible. This is best achieved through a personalized approach to both home care and office hygiene visits, whose duration and frequency should be determined according to the individual patient's need.

How Implants Differ From Teeth

The main difference between teeth and dental implants lies in their tissue attachments. The peri-implant attachment is quite different from the periodontal attachment. The peri-implant attachment is lacking around the implant, and at the gingival margin the

gingival fibers run circumferential, parallel to the implant, so they are not inserted inside the abutment or the implant surface, unlike around a tooth, where there is a hemidesmosomal attachment to the gingiva. Therefore, the peri-implant soft-tissue junction does not create a seal as the periodontium does.

Peri-Implantitis

Dental implant maintenance is especially important in light of evidence that, according to the 3rd EAO Consensus Conference, peri-implantitis defined by Froum and Rosen as peri-implant disease that has progressed beyond peri-implant mucositis to the point of bone loss¹ develops within 5 years of placement among one in five patients.²

While the stated goal of dental implant maintenance is to reduce the number of peri-implantitis cases behind such statistics, the real objective is to eliminate the condition entirely, ideally through prevention, but certainly at the first sign of inflammation—ie, peri-implant mucositis—which is seen in nearly 63% of the patients.

Risk Factors for Peri-implantitis/ Restoration Failure

The author's position is that peri-implantitis and subsequent implant failure could best be avoided by understanding and addressing the factors that place some patients at higher risk

Peri-implant disease that has progressed beyond peri-implant mucositis to the point of bone loss develops within 5 years of placement among one in five patients.

for its development. Among them are local factors such as previous or current periodontitis, residual subgingival cement, occlusal overload, foreign body reaction, and poor oral hygiene, which can be countered by teaching patients the right oral hygiene techniques. Because patients' peri-implant health is affected by systemic issues such as smoking, diabetes, and generalized chronic inflammation, it is

important to ensure a good patient history and referral to the right medical professional.³

How Implants Should be Maintained at Home

Homecare generally includes brushing, flossing, and the use of mouth rinses. Mainly because patients may ask about it, doctors should also be aware of an Ayurvedic technique called oil pulling, where oil is swished between the teeth or implants for about 20 minutes. Although there are some studies suggesting this method reduces bacteria and gingivitis, it has not been studied to determine its effect on peri-implantitis or peri-implant mucositis and should, therefore, not be recommended.

Toothbrushing

The evidence is somewhat mixed on whether powered or manual toothbrushes are best for implants. Results of a 6-year multicenter study reported significant decrease in bleeding on probing (BOP) and plaque using electric brushes.⁴ Another paper based on a systematic review of self-performed oral hygiene practices for optimal maintenance of dental implant-supported restorations revealed a lack of evidence to support best practices, but concluded that powered toothbrushes were found to perform better than manual toothbrushes.⁵ Ultimately, the right tool depends most of all on the patient's willingness and ability to use it properly. For patients with

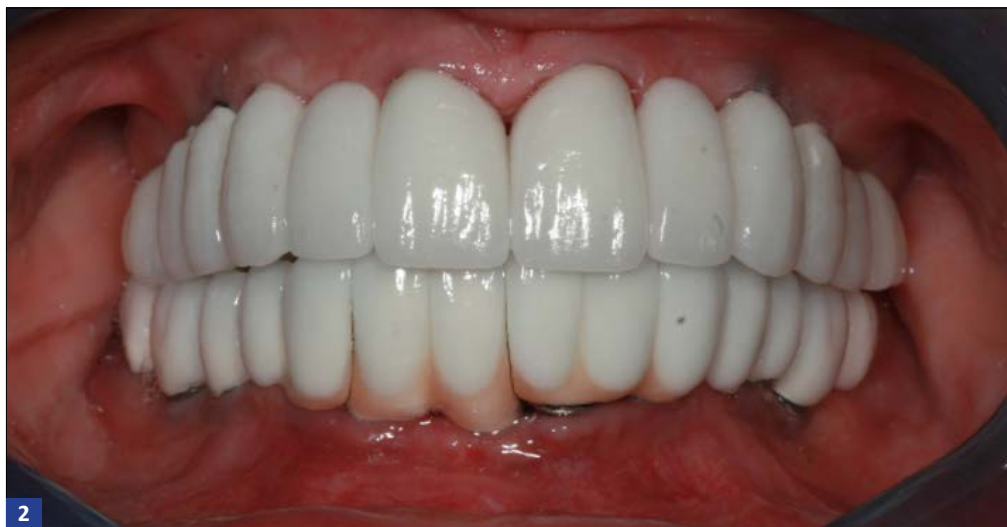
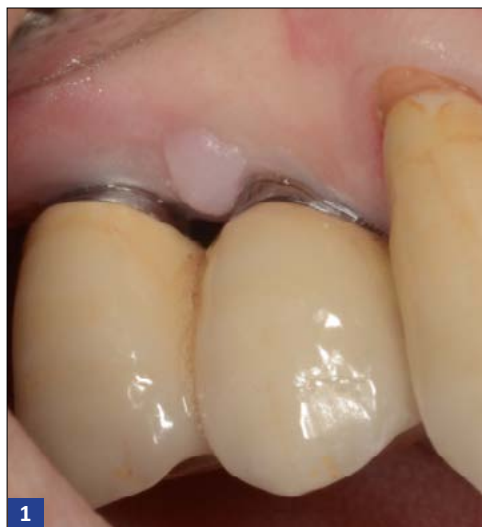
Fig 1. Improvement in tissue health around an implant after use of an oral irrigator. **Fig 2.** Full-arch prosthesis showing minimal-to-no plaque around both the top and bottom peri-implant tissues after oral irrigator use.

Dental Implant Maintenance

poor dexterity, an electric toothbrush is specifically recommended.

Mouthrinses

There is a fair amount of literature on mouthrinses. For example, chlorhexidine irrigation seems to be more effective in reducing plaque and bleeding than swishing it alone, and swishing Listerine® mouthwash was also found to be better than saline with regard to reducing plaque and bleeding around dental implants. These findings from the Cochrane Database of Systemic Review done in 2010⁶ found no difference between toothbrushes or between chlorhexidine rinse or saline rinse. More studies are needed to verify whether swishing Listerine mouthwash is actually better than chlorhexidine.

Flossing/Interdental Devices/Oral Irrigator

Numerous tools are available for interdental cleaning. Interdental brushes can be helpful in patients who have implant-supported prostheses on bars, but they must have the dexterity to use them properly. Such patients may also have difficulty getting underneath the prosthesis with floss. The author recommends the use of oral irrigators/water flossers—particularly for patients with limited manual dexterity—which are supported by studies published in 2013⁷ and 2015.⁸ Both of these studies found that water flossers are 80% more effective than string floss in reducing bleeding around dental implants after 30 days.

There are a wide variety of such interdental products on the market. For implant patients, the author recommends choosing an oral irrigator that pulsates and has at least two tips: the universal tip and the dental implant tip with three tufts. A Tufts University School of Dental Medicine study found a water flosser with implant tip was 145% more effective than string floss around implants when used in conjunction with a manual toothbrush.⁹ Significant reduction of gingival bleeding at 2 weeks and 30 days, respectively, were reported.⁹ Improvement in the health of tissues around implants can be seen in one patient who presented with inflammation around an implant (Figure 1), and another patient with a full-arch prosthesis that now has minimal-to-no plaque around both the top

Numerous tools are available for interdental cleaning. Interdental brushes can be helpful in patients who have implant-supported prostheses on bars, but they must have the dexterity to use them properly.

and bottom peri-implant tissues (Figure 2).

An oral health study from the University of Southern California's Center for Biofilm Research reported that holding a water jet over the surface of the implant tooth removed 99.9% of mature plaque biofilm in only 3 seconds.¹⁰

Establishing a Good Implant Maintenance Program ***Brushing and Flossing***

Recommendations to patients should consider the individual—including dexterity, motivation, and the type of restoration. Unless there are dexterity problems, the author generally leaves it to implant patients to choose whether to use an electric or manual toothbrush, but based on the literature, strongly recommends that they incorporate a water flosser or oral irrigator. Patients who are avid string flossers should be cautioned about the risk of injury to gingiva and peri-implant tissues using the floss because the attachment of the peri-implant tissues is not as strong as the periodontium.^{11,12} To prevent permanent damage to those tissues, they may be switched to an oral irrigator.

Educating Patients About the Importance of Maintenance

In addition to the challenge of convincing

patients to adhere to proper home maintenance is getting them to comply with recommended office visit recommendations. For that reason the team must take the time to educate patients about not only the methods, but the importance of the maintenance visit. Patients should be made aware that this is not just to prevent peri-implantitis—which can be costly, time-consuming, and unpredictable—but to maintain their oral health for the sake of their overall health, especially if they are suffering from or are at risk for chronic illnesses.

Recall Visit Management for Implant Patients ***Intervals Between Appointments***

Determining the interval between appointments—anywhere from 1 to 6 months—should be personalized, based on the patient's ability to perform good oral hygiene at home. There is no protocol established in the literature for the 6-month interval for implant patients. To prevent the development of peri-implantitis in a patient who has difficulty cleaning underneath the prosthesis, an interval of 1 or 2 months may be appropriate.

Length of Appointments

Then, too, to consider is the length of the appointment—anywhere from 30 to 60 minutes, depending on the complexity of the care rendered in the office. For example, for a patient with six implants and no dentition, 30 minutes may be sufficient, but most patients have mixed dentition and implants, so usually a 45- to 60-minute dental maintenance visit is necessary in order to complete good record-taking, patient education, and plaque removal.

Implant-Related Record-Keeping

Records such as photographs and radiographs taken by the hygienist at the implant maintenance appointment show how the patient is maintaining over time. Ideally, radiographs should be taken once a year. Pocket depths, BOP, inflammation, and plaque levels should be reported. Occlusion and mobility also should be noted. Baseline photographs, radiographs, and probing depths should be taken at the time of implant placement and prosthesis delivery, so changes can be monitored over time.

Medical History, Including Supplements

In addition to assessing the patients' hygiene, oral health, systemic health, and medications, it is important to determine their wellness status and ask about nutritional supplements, because 68% of Americans today take some kind of supplements that can affect oral health.¹³ If they do not take supplements, that could be a problem, too. An example is a lack of vitamin D—a systemic deficiency that increases the risk of osteoporosis, high blood pressure, allergies, colds and flu, mental health, and heart problems. An adequate level, on the other hand, positively affects oral health by reducing inflammation and modulating cell growth and immune function. Vitamin D level has also been inversely associated with gingival bleeding and level of periodontal disease.¹⁴

Therefore, the author suggests gathering information about the patient's vitamin D level or asking them to be tested. Optimal vitamin D recommendations (Table 1) are now rising in keeping with research that supports it.¹⁴

Radiographs

Given patient concerns about radiation exposure, it is important to know how, when, and why radiographs should be taken. Although there are concerns about radiation, radiographs make it possible to determine bone levels at baseline—ie, at implant and restoration insertion—and to monitor them over time. Vertical radiographs should be as parallel as possible to the implant body, so that the implant threads are clearly visible. Typically, periapicals should be taken once a year around dental implants. Figure 3 and Figure 4 shows bone loss up to the fifth and sixth thread.

Probing

It is important to know when and how to probe for the same reasons as taking radiographs—to establish initial pocket depths at baseline (insertion of the restoration) and to monitor for changes over time. For this, a traditional periodontal probe should be used, exerting light force, 0.25 N. However, unlike bone loss, neither BOP nor probing depths—even as much as 6 mm—are correlated to bone loss around implants, according to the Estepona consensus on peri-implantitis 2012.¹⁵

TABLE 1. VITAMIN D RECOMMENDATIONS FROM THE COMMITTEE OF THE INSTITUTE OF MEDICINE

Recommended Serum 25-Hydroxyvitamin D Concentrations

Nmol/L	Ng/ML	Health Status
<25	<10	Severe deficiency. Supplementation recommended.
25-50	10-20	Deficiency. Supplementation recommended.
50-100	20-40	Suboptimal levels. Supplementation recommended.
100-200	40-80	Optimal levels.
>250	>100	Elevated

Source: Moldovan S. *Inside Dentistry*. 2015;11(7):45-52.14

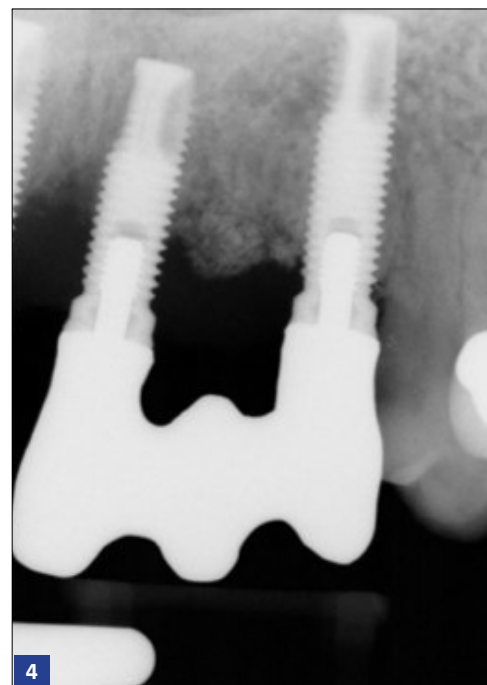
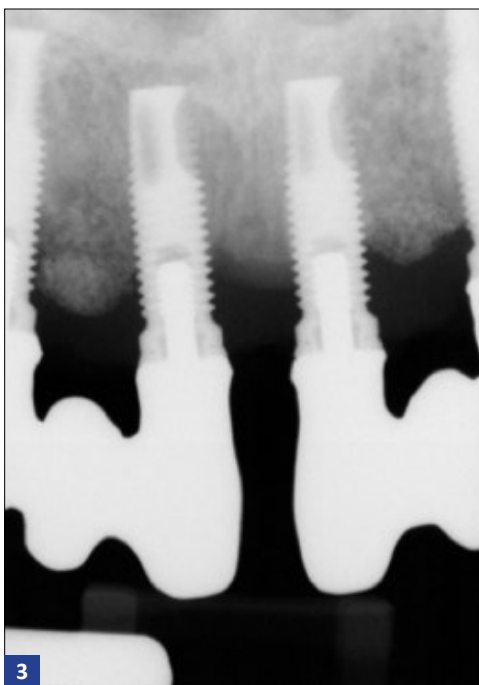


Fig 3. and Fig 4. Radiographs showing bone loss around an implant.

Assessing Plaque Level

The plaque/calculus level should also be documented regularly for signs of changes. The location (supragingival, subgingival, or on the prosthesis itself), severity (mild, moderate, severe), and whether it is anterior/posterior, buccal/lingual, and upper should be documented to see if there is improvement at the next hygiene visit.

According to the literature, the location of plaque may affect its accumulation. Quirynen et al¹⁶ found minor differences in the amount of plaque on rough versus smooth surfaces,

but Wennerberg et al¹⁷ reported similar plaque formation. Baldi et al concluded that dual acid-etched surfaces have greater plaque accumulation than machined surfaces, but there is less marginal bone loss.¹⁸ Because etched or rough surfaces around dental implants have greater plaque accumulation but less marginal bone loss than machined surfaces, it is best to try to protect implant surfaces from plaque exposure but to correct it if it has been exposed.

Plaque Accumulation Removal

While some hygienists like to use plastic

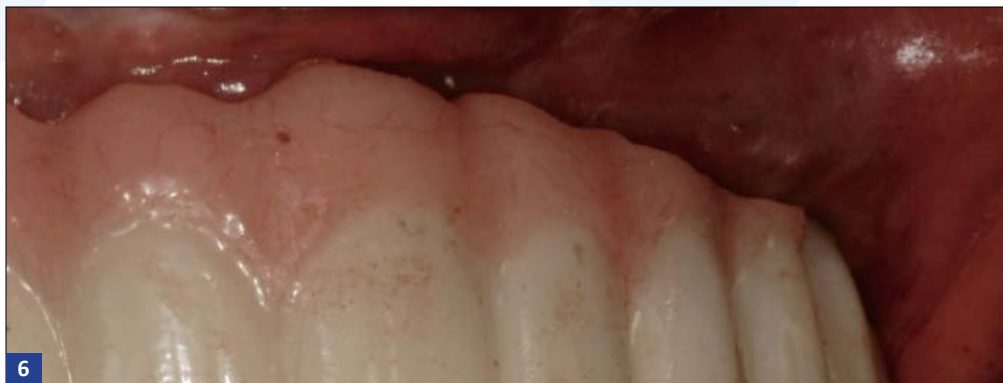
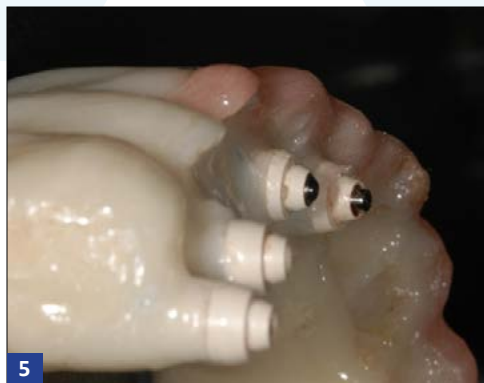
Fig 5. and Fig 6. Concavity in the buccal surface of the prosthesis design. The resultant imperfect fit creates a “trap” for plaque.

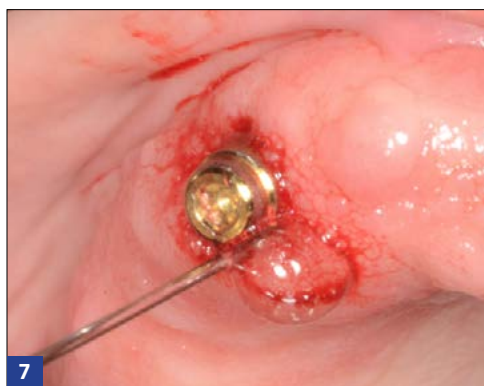

Fig 7. Cannula used to administer ozone subgingival therapy for treatment of peri-implant mucositis.

Checking Occlusion/ Occlusal Overload

That the implant patient's occlusion should be checked at every hygiene visit is suggested by the literature, including a monkey study by Isidor associating a loss of osseointegration with occlusal overload of oral implants²¹ and a review by Fu et al²² in which unbalanced occlusion affected the marginal bone loss around dental implants. A study by Miyata et al,²³ which examined the influence of experimental occlusal overload on peri-implantitis in monkeys, showed that bone resorption around implants tended to increase with 180 µm or more excessive height of the superstructure, suggesting that minor occlusal overload is not a significant concern. However, over time—especially with mixed dentition, eg, porcelain or zirconia crowns, which wear differently than enamel—the implant can suddenly be in hyperocclusion associated with bone loss, which could eventually lead to implant loss. Therefore, occlusal overload should be checked and, if necessary, adjusted every 6 months to prevent problems.

Dealing With Residual Cement

Residual cement left subgingivally can lead to bone loss and implant failure, as observed by Wilson,²⁴ whose findings support scrupulous cement removal at the time of cementation, considering the unintended presence of cement as a potential cause when signs of peri-implant disease are seen. Ideally, whenever possible, a screw-retained restoration should be fabricated. If cementation is unavoidable due to the angle of the implant, then it is important to use a radio-opaque cement,

which is visible on x-rays, to facilitate complete removal.²⁵ It is also important that the margins of the implant crown are not placed subgingivally to allow for visualization of the cement and easy removal.

Bacterial Culture

The literature offers some insight about whether or not to culture patients who have peri-implantitis or some slight suppuration from mucositis. A study by Renvert et al²⁶ did not find any significant difference between the bacteria in nearly 1,000 implants, whether or not affected by peri-implantitis. These findings suggest peri-implant disease is a factor of the amount of bacteria and the genetic susceptibility of the patient, not necessarily the type of bacteria that is in the mouth. Similarly, Hultin et al²⁷ found high levels of periodontal pathogens in peri-implantitis.

Both studies suggest that it is not necessary to culture right away. Most important is, if there is a significant amount of suppuration inflammation, the area should be irrigated locally with antimicrobials; systemic antibiotics are really not necessary. In short, culturing should be done on a case-by-case basis, not for everyone with peri-implantitis.

Understanding Prosthesis Contours and Cleansability

The contours of the prosthesis can have a significant impact on the patient's ability to maintain good oral hygiene at home and keeping healthy peri-implant tissues. The practitioner should be aware of this issue and make sure restorations are as cleansable as possible. For example, a concave surface from the abut-

scalers, studies show that all scalers, whether filled or unfilled resin or titanium, leave scratches on the titanium surface.¹⁹ Instead, hygienists can use ultrasonic devices that come with the rubber tip protectors that cause less damage or scratches to the abutment. Hygienists should be mindful of minimizing scratches on the smooth implant/abutment surface, because scratches can actually increase the plaque accumulation.

The author does not recommend using air-powder abrasive for cleaning around implants to avoid bleeding particles around the tissues. A study by Tastepe and others noted minor surface changes on titanium treated with air-powder abrasives, with treatment results influenced by the powder type being used, the application time, and whether the powder was applied surgically or nonsurgically; remnants were observed on and impacted in the titanium surface.²⁰

ment to the buccal surface is a plaque trap and should be immediately corrected (Figure 5 and Figure 6).

It is particularly important to ensure that the space beneath the prosthesis be designed to maximize cleansability. To prevent food impaction, a gap beneath the prosthesis should be minimized through correction, such as realignment. In general, all intaglio surfaces of the prosthesis should be convex or flat, and buccolingual dimensions should be as narrow as possible, but not so thin that the prosthesis is likely to break. The patient must be able to get the water flosser all the way through and underneath the prosthesis.

The clinician should also be aware of the importance of having keratinized attached tissue around dental implants, and monitor for it. Thicker keratinized attached gingiva creates a better seal around the abutment and prevents plaque and food accumulation.

Using Ozone

To combat fungus, bacteria, and parasites that may contribute to peri-implant disease, the author has incorporated ozone in recent years. This ozone, which is three molecules of oxygen that are used in the form of gas or ozonated water to clean in both dentistry and medicine, safely helps kill any fungus, bacteria, or parasite on contact. However, although it is natural and safer than bleach, because the only two tissues in the human body that do not have anti-oxygen capacity are the eyes and the lungs, it should not be inhaled, and eye protection is needed. Proper training is required if ozone is to be incorporated in the dental office.

Ozone is used in peri-implantitis or where the beginning of inflammation is seen in mucositis by using a cannula (Figure 7) to blow the gas directly underneath the tissues affected. Although this has been around for more than 100 years, until recently there were few studies, likely due to the advent of antibiotic resistance to antimicrobials. However, one that studied the influence of gaseous ozone in peri-implantitis reported that a 24-second treatment around areas of the inflammation can sterilize and eliminate the microorganisms *Strep sanguinis* and *Porphyromonas gingivalis* without affecting the osteoblasts and the tissue cells.²⁸

The dental team needs to help them understand why it is important to recognize initial mucositis or initial changes because it is more predictable to correct them in the beginning.

Improving Hygiene Compliance

There are several components to improving patients' hygiene compliance: understanding their desires; identifying causes of noncompliance; making hygiene visits pleasurable; and changing their protocol and getting them involved in decisions made. These concepts apply to all patients, but the stakes—uncontrolled disease leading to implant failure—are especially high for implant patients. Therefore, the dental team needs to help them understand why it is important to recognize initial mucositis or initial changes because it is more predictable to correct them in the beginning. It is important to work with patients who are not receptive to that message or are negligent about their hygiene appointments. A protocol designed in keeping with their desires and abilities and that is developed with their involvement is most likely to be effective. For example, a patient who cannot or will not use string floss should be changed to an oral irrigator, and those unwilling or unable to practice optimal homecare should be seen in the office more frequently.

Conclusion

Optimal peri-implant maintenance is based on several pillars. First, the clinicians and all dental team members must listen carefully to

their patients to understand their desires and goals. Based on individual patients' abilities and needs, implant patients should be educated on a personalized program of home care. Further, the dental team should ensure that hygiene interval schedules and appointment lengths are customized to meet the individual patient's needs.

ABOUT THE AUTHOR

Dr. Moldovan is a periodontist and nutritionist whose practices in Los Angeles, California, and New York City are primarily devoted to implant therapy.

REFERENCES

1. Froum SJ, Rosen PS. A proposed classification for peri-implantitis. *Int J Periodontics Restorative Dent*. 2012;32(5):533-540.
2. Atieh MA, Alsabeeha NH, Faggion CM Jr, Duncan WJ. The frequency of peri-implant diseases: A systematic review and meta-analysis. *J Periodontol*. 2013;84(11):1586-1598.
3. Daubert DM, Weinstein BF, Bordin S, et al. Prevalence and predictive factors for peri-implant diseases and implant failure: a cross-sectional analysis. *J Periodontol*. 2015;86(3):337-347.
4. Truhlar RS, Morris HF, Ochi S. The efficacy of a counter-rotational powered toothbrush in the maintenance of endosseous dental implants. *J Am Dent Assoc*. 2000;131(1):101-107.
5. Louropoulou A, Slot DE, Van der Weijden F. Mechanical self-performed oral hygiene of implant supported restorations: a systematic review. *J Evid Based Dent Pract*. 2014(Jun);14 Suppl:60-69.e1.
6. Grusovin MG, Coulthard P, Worthington HV, Esposito M. Maintaining and recovering soft tissue health around dental implants: a Cochrane systematic review of randomised controlled clinical trials. *Eur J Oral Implantol*. 2008;1(1):11-22.
7. Magnuson B, Harsono M, Stark PC, et al. Comparison of the effect of two interdental cleaning devices around implants on the reduction of bleeding: a 30-day randomized clinical trial. *Compend Contin Educ Dent*. 2013;34(Spec No 8):2-7.
8. Ioannidis A, Thurnheer T, Hofer D, et al. Mechanical and hydrodynamic homecare devices to clean rough implant surfaces - an in vitro polyspecies biofilm study. *Clin Oral Implants Res*. 2015;26(5):523-528.
9. The Effect of a Water Flosser with Plaque Seeker Tip® on Gingival Bleeding for Implant Patients. Presented at the International Association of

Dental Implant Maintenance

Dental Research, Seattle, WA, USA. March 23, 2013. Abstract #3761.

10. Gorur A, Lyle DM, Schaudinn C, Costerton JW. Biofilm removal with a dental water jet. *Compend Contin Educ Dent*. 2009;30(Spec No 1):1-6.

11. Misch, CE. *Contemporary Implant Dentistry*. 3rd ed. St. Louis, MO: Mosby Elsevier; 2008:75-76.

12. Hallmon WW, Waldrop TC, Houston GD, Hawkins BF. Flossing clefts. Clinical and histologic observations. *J Periodontol*. 1986;57(8):501-504.

13. Council for Responsible Nutrition press release. Most Americans take—and trust—supplements. New Hope Network website. October 23, 2015. <http://newhope.com/news-analysis/most-americans-take-and-trust-supplements>. Accessed April 25, 2016.

14. Moldovan S. Update on nutrition for better healing. *Inside Dentistry*. 2015;11(7):45-52.

15. Albrektsson T, Buser D, Chen ST, et al. Statements from the Estepona consensus meeting on peri-implantitis, February 2-4, 2012. *Clin Implant Dent Relat Res*. 2012;14(6):781-782.

16. Quirynen M, van der Mei HC, Bollen CM, et al. An in vivo study of the influence of the surface roughness of implants on the microbiology

of supra- and subgingival plaque. *J Dent Res*. 1993;72(9):1304-1309.

17. Wennerger A, Sennerby L, Kultje C, Lekholm U. Some soft tissue characteristics at implant abutments with different surface topography. A study in humans. *J Clin Periodontol*. 2003;30(1):88-94.

18. Baldi D, Menini M, Pera F, et al. Plaque accumulation on exposed titanium surfaces and peri-implant tissue behavior. A preliminary 1 year clinical study. *Int J Prosthodont*. 2009;22:447-455.

19. Hasturk H, Nguyen DH, Sherzai H, et al. Comparison of the impact of scaler material composition on polished titanium implant abutment surfaces. *J Dent Hyg*. 2013;87(4):200-211.

20. Tastepe CS, van Waas R, Liu Y, Wismeijer D. Air powder abrasive treatment as an implant surface cleaning method: a literature review. *Int J Oral Maxillofac Implants*. 2012;27(6):1461-1473.

21. Isidor F. Loss of osseointegration caused by occlusal load of oral implants. A clinical and radiographic study in monkeys. *Clin Oral Implants Res*. 1996;7(2):143-152.

22. Fu JH, Hsu YT, Wang HL. Identifying occlusal overload and how to deal with it to avoid marginal bone loss around implants. *Eur J Oral Implantol*. 2012;5(Suppl):S91-S103.

23. Miyata T, Kobayashi Y, Araki H, et al. The influence of controlled occlusal overload on peri-implant tissue. Part 3: A histologic study in monkeys. *Int J Oral Maxillofac Implants*. 2000;15(3):425-431.

24. Wilson TG Jr. The positive relationship between excess cement and peri-implant disease: A prospective clinical endoscopic study. *J Periodontol*. 2009;80(9):1388-1392.

25. Burbano M, Wilson TG Jr, Valderrama P, et al. Characterization of Cement Particles Found in Peri-implantitis-Affected Human Biopsy Specimens. *Int J Oral Maxillofac Implants*. 2015;30(5):1168-1173.

26. Renvert S, Roos-Jansåker AM, Lindahl C, et al. Infection at titanium implants with or without a clinical diagnosis of inflammation. *Clin Oral Implants Res*. 2007;18(4):509-516.

27. Hultin M, Gustafsson A, Hallström H, et al. Microbiological findings and host response in patients with peri-implantitis. *Clin Oral Implants Res*. 2002;13(4):349-358.

28. Hauser-Gerspach I, Vadaszan J, Deronjic I, Gass C, et al. Influence of gaseous ozone in peri-implantitis: bactericidal efficacy and cellular response. An in vitro study using titanium and zirconia. *Clin Oral Investig*. 2012;16(4):1049-1059.

CONTINUING EDUCATION 2

QUIZ

Dental Implant Maintenance

Sanda Moldovan, DDS, MS, CNS



This article provides 2 hours of CE credit from Dental Learning Systems, LLC. Log on to cdeworld.com/go/ucci-ce8 to take the CE quiz for a fee of \$18. You may also phone your answers in to 877-423-4471 or fax them to (215) 504-1502. Be sure to include your name, address, telephone number, and last 4 digits of your Social Security number.

[CLICK HERE TO TAKE THE QUIZ ONLINE](#)

- The main difference between teeth and dental implants:**
 - is their appearance.
 - is the biological width.
 - lies in their tissue attachments.
 - is that implants require no hygiene care.
- Peri-implantitis, defined as peri-implant disease that has progressed beyond peri-implant mucositis to the point of bone loss, has been found to develop within:**
 - 6 months of placement among one in two patients.
 - 2 years of placement among one in four patients.
 - 5 years of placement among one in three patients.
 - 5 years of placement among one in five patients.
- Systemic issues that affect peri-implant health include:**
 - smoking.
 - diabetes.
 - generalized chronic inflammation.
 - All of the above
- Studies have found that what are 80% more effective than string floss in reducing bleeding around dental implants after 30 days?**
 - manual toothbrushes
 - water flossers
 - toothpicks
 - oil pulling techniques
- Implant maintenance recommendations to patients should consider the individual's:**
 - socioeconomic status.
 - dexterity.
 - hemidesmosomal attachment.
 - vitamin B intake.
- The interval between recall appointments for implant patients should be:**
 - a standard 6 months.
 - every 2 weeks.
 - after they have developed peri-implantitis.
 - personalized, based on the patient's ability to perform good oral hygiene at home.
- In addition to assessing the patient's hygiene, oral health, systemic health, and medications, it is important to ask about their use of?**
 - nutritional supplements
 - ozone gas
 - all-natural toothpaste
 - chlorhexidine-based mouthrinse
- Vertical radiographs should be as parallel as possible to the implant body, so that:**
 - the implant threads are clearly visible.
 - bone levels will improve.
 - radiation exposure will be lessened.
 - All of the above
- Hygienists should be mindful of minimizing scratches on the smooth implant/abutment surface, because scratches:**
 - will be severely painful.
 - can increase plaque accumulation.
 - lead directly to peri-implantitis.
 - significantly decrease the implant's survival rate.
- If cementation is unavoidable due to the angle of the implant, it is important to use what type of cement?**
 - radiolucent
 - radio-opaque
 - self-etch
 - universal

Course is valid from 7/1/2017 to 7/31/2020. Participants must attain a score of 70% on each quiz to receive credit. Participants receiving a failing grade on any exam will be notified and permitted to take one re-examination. Participants will receive an annual report documenting their accumulated credits, and are urged to contact their own state registry boards for special CE requirements.

ADA CERP® | Continuing Education Recognition Program

Dental Learning Systems, LLC, is an ADA CERP Recognized Provider. ADA CERP is a service of the American Dental Association to assist dental professionals in identifying quality providers of continuing dental education. ADA CERP does not approve or endorse individual courses or instructors, nor does it imply acceptance of credit hours by boards of dentistry. Concerns or complaints about a CE provider may be directed to the provider or to ADA CERP at www.ada.org/cerp.



Approved PACE Program Provider FAGD/MAGD Credit Approval does not imply acceptance by a state or provincial board of dentistry or AGD endorsement
1/1/2017 to 12/31/2022
Provider #: 209722

FEATURED PARTNER BENEFIT

Is Your Sterilizer Effective?

United Concordia has partnered with Steri Check Systems* to offer sterilizer monitoring (spore testing) at a discounted rate. This is a value-added benefit available to providers currently participating in one or more United Concordia networks.

Features of Steri Check Monitoring Service:

- Can be used to monitor steam, chemical vapor, dry heat and ethylene oxide gas sterilizers
- Includes laboratory culturing service, prepaid postage mailers and free shipping
- Provides a certificate of compliance, sterilizer monitoring log and full documentation
- Cost-effective and easy to use.

Monitoring Frequency	Regular Rate	Discount Rate
Spore-Wise * 52 (weekly testing)	\$269/yr	\$157/yr
Spore-Wise * 26 (bi-weekly testing)	\$169/yr	\$119/yr
Spore-Wise * 12 (monthly testing)	\$79/ yr	\$64/yr

Both the ADA and CDC recommend periodic use of biological indicators (spore tests) to verify the proper functioning of sterilization cycles. For the health and safety of your patients and staff, enroll with Steri Check today and comply with proper infection control protocol.

*Steri Check Systems, Inc. is not affiliated with United Concordia, and is solely responsible for its own products and services.

To take advantage of this special savings and monitor your office sterilizers at the special rates listed above, complete and return the attached order form or call Steri Check at **800-67-STERI (800-677-8374)**.

Mail to: Steri Check Systems, Inc., P.O. Box 659, Deer Park, NY 11729 • Or, Fax: (631) 242-9546 • Or, eMail stericheck@aol.com

Sterilizer Make: _____ ☐ Steam ☐ Dry Heat ☐ Chemical ☐ Gas

Monitoring Frequency: ☐ 52 (Weekly) ☐ 26 (Bi-weekly) ☐ 12 (Monthly)

Dentist or Group Name: _____
(to appear on certificate)

Address: _____ City: _____ State: _____ Zip: _____

Phone: _____ Fax: _____ Contact Name: _____

Email Address: _____ UCCI Provider Number: _____

Signature: _____

☐ Payment Attached (Payable to Steri Check Systems, Inc.)

Credit Card: ☐ Visa ☐ Mastercard

Credit Card Number: _____ Expiration Date: _____ Security Code:

Credit Card Billing Address: _____

Closing a Black Triangle WITH RESIN COMPOSITE

Marcos A. Vargas, DDS

ABSTRACT

A patient presented with a desire to solve the esthetic problem of a lack of papilla between the maxillary central incisors, known as a “black triangle.” After considering several options, he chose to have the space eliminated through a resin composite technique. The result left him pleased with his appearance. This case report details the steps that were taken to achieve the successful outcome.

The goal of esthetic dentistry is to create a pleasant smile in which harmony exists between lips, teeth, and gingiva. Most patients see the lack of papilla, resulting in a “black triangle,” as an unesthetic feature.¹⁻³ Predictably resolving this problem can be daunting and cumbersome for the dentist. The purpose of this case report is to present a technique in which resin composite is used to augment the proximal contour of the teeth adjacent to the black triangle, thus eliminating this problem.

Treatment Options

The patient presented with a chief complaint that he described as a “dark area in between my two front teeth” (Figure 1). He wanted to know his options to remediate this esthetic problem in a conservative and economical manner.

Several treatment options were suggested to the patient:⁴⁻⁶ 1) Do nothing. The author explained to the patient that treatment to solve a cosmetic issue is elective. 2) Add resin composite to each central incisor to create a longer contact, reducing the distance between the contact point and the crest of the bone. 3) Choose partial porcelain veneers. The patient decided to have resin composite added to close the space.

The Resin Composite Procedure

Shade selection was made and topical anesthetic given before the application of the rubber dam. Rubber dam isolation with ligatures is ideal for these types of cases because it provides absolute isolation and pushes the gingival tissues apically, allowing access and visibility to subgingival areas. Figure 2 and Figure 3 depict the difference in visibility and access.

A slurry of pumice and interproximal strips were used to provide a clean surface for bonding. Subsequently, 37% phosphoric acid was applied through a rubbing motion with a brush tip for 30 seconds (Figure 4). A copious amount of water was used to remove the etchant, and the surface was completely dried. Adhesive was applied (Figure 5), dried for 30 seconds, and light polymerized for 20 seconds.

An initial increment of extra white enamel was placed on the mesiofacial incisal line angle of the right central incisor (Figure 6 and Figure 7).

A thin-bladed composite instrument, the interproximal carver (IPC) (Figure 8), was used for the initial increment to be thinned over the distal aspect to provide adequate blending. The remaining resin composite was then pushed mesially and lingually to

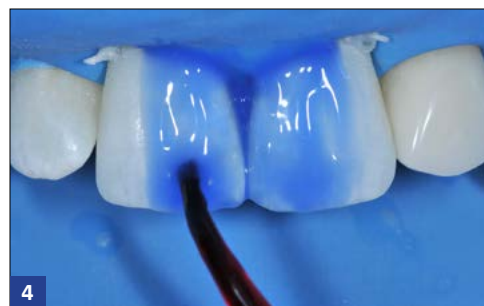
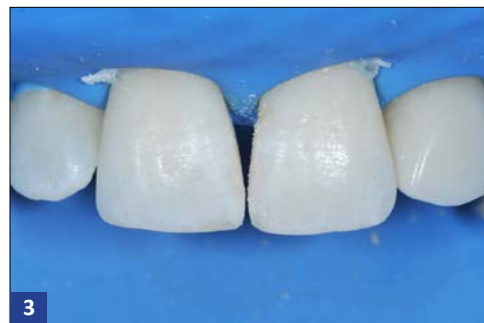
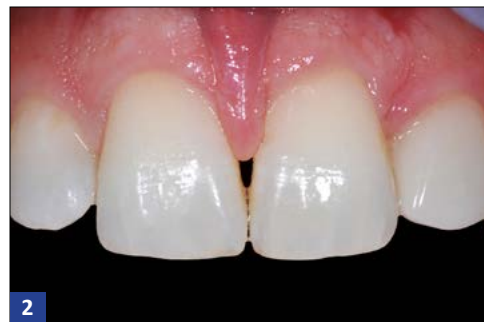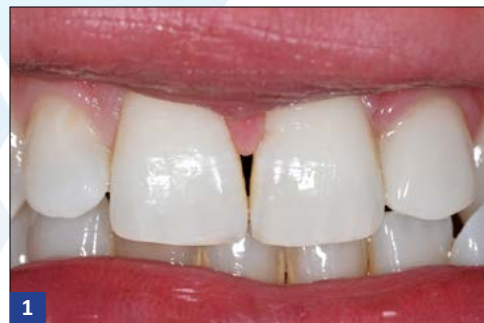Fig 1. The patient presented with a dark area between teeth Nos. 8 and 9, known as the “black triangle.” **Fig 2 and Fig 3.** The difference in visibility and access with a rubber dam (Fig 3) is shown. **Fig 4.** Application of 37% phosphoric acid.

Closing a Black Triangle With Resin Composite

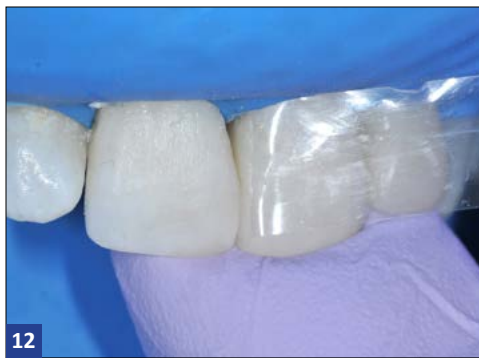
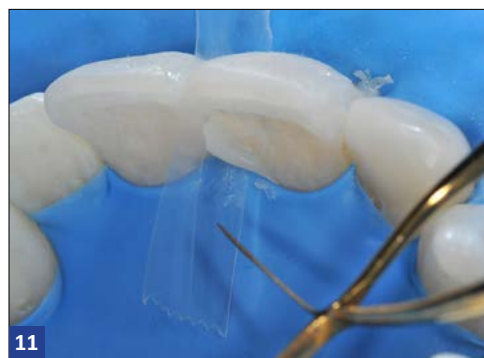
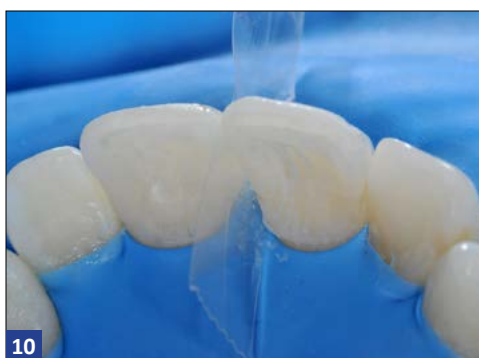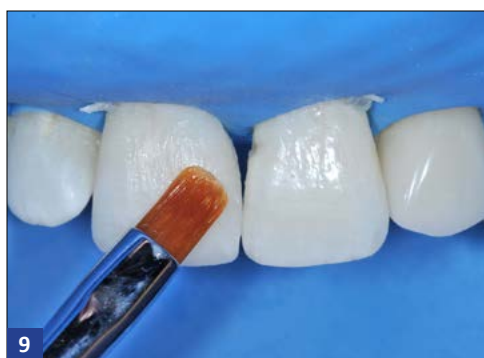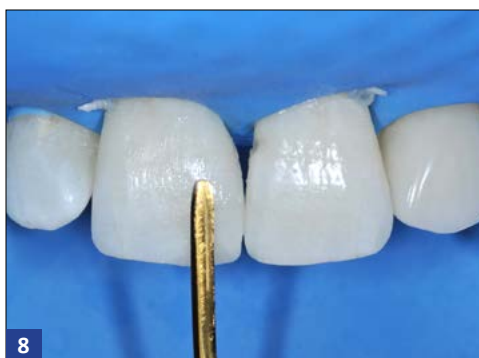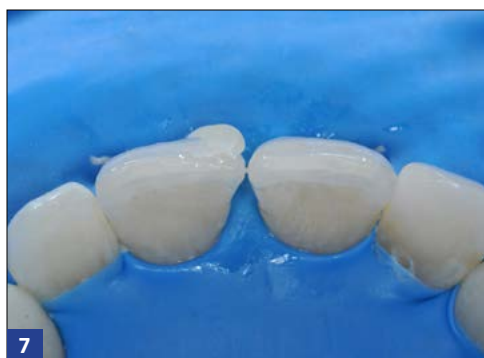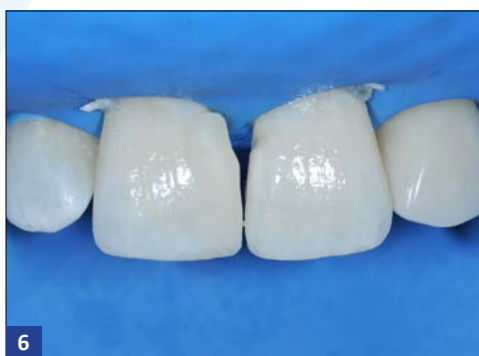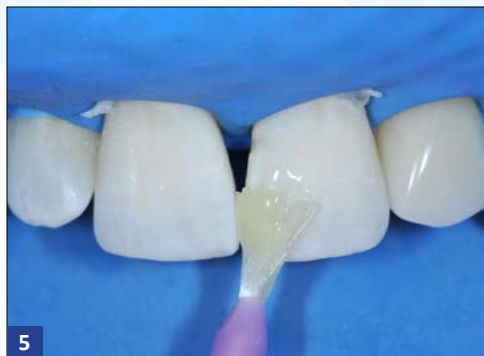Fig 5. Application of adhesive. **Fig 6 and Fig 7.** Placement of enamel on the mesiofacial incisal line angle of the right central incisor. **Fig 8.** An IPC was used to provide adequate blending. **Fig 9.** A flat brush was used to leave a smooth surface. **Fig 10.** A small amount of composite was placed between the mylar strip and the tooth. **Fig 11 and Fig 12.** The mylar strip was held against the palatal surface and then gently pulled toward the facial surface.

form the interproximal contour. Careful attention was ensured to prevent creating an overhang. A flat brush was used to leave a smooth surface before light polymerization (Figure 9).

An increment of composite was then placed over the facial aspect of tooth No. 9 and blended in a similar manner as was done with tooth No. 8. This step was done simply to create the facial proximal aspect. The increment was not pushed palatally because the remaining space was not as big and did not allow for freehand interproximal contouring of the composite. The increment was then smoothed with a brush and light polymerized with a mylar strip between the central incisors to avoid bonding them together.

Occlusion was checked after removal of the rubber dam. After the soft tissue and papilla were released from the rubber dam, the black triangle appeared completely closed.

After polymerization, a small amount of composite was placed between the mylar strip and the tooth from the lingual angle (Figure 10).

The mylar strip was then held closed against the palatal surface and gently pulled toward the facial surface. This process would carry the material facially to close the mesiopalatal embrasure completely (Figure 11 and Figure 12). The increment surface

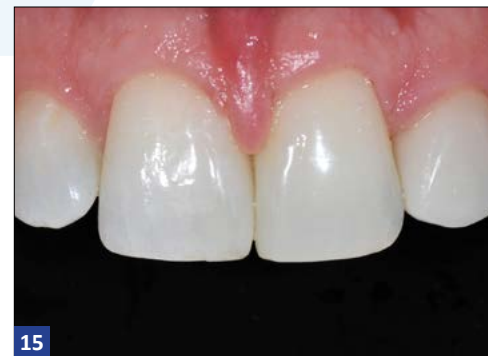
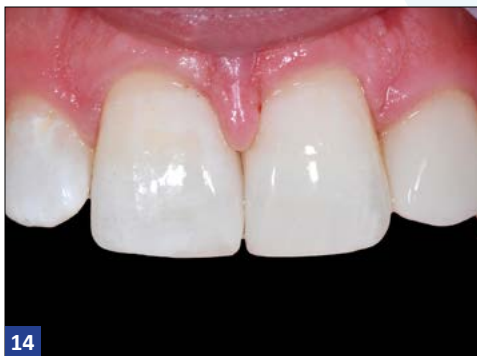
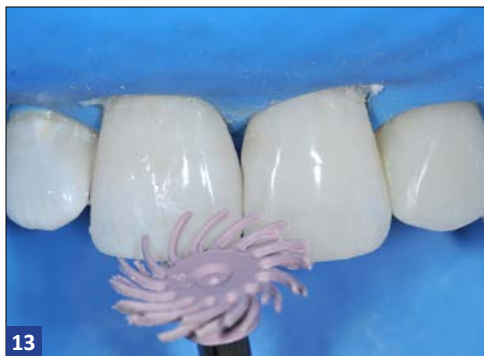Fig 13. Contouring and polishing was done with a carbide disk, rubber cups, and rotating wheels. **Fig 14.** The black triangle appeared completely closed. **Fig 15.** Final check 4 weeks later.

was smoothed and light polymerized palatally and facially for 20 seconds each.

Contouring and polishing to obtain an enamel luster and blending into the enamel was accomplished using a carbide disk, rubber cups, and rotating wheels (Figure 13). Interproximal finishing and polishing was performed with sequential finishing strips.

Final Results

Occlusion was checked after removal of the rubber dam. After the soft tissue and papilla were released from the rubber dam, the black triangle appeared completely closed (Figure 14). Dental floss was used to ensure no overhangs had been left, and its use was demonstrated to the patient for proper hygiene.

The patient returned 4 weeks later for a final check (Figure 15). The patient was completely satisfied and pleased with the esthetic result. He maintained good hygiene, and no bleeding was detected on probing the area.

ABOUT THE AUTHOR

Marcos A. Vargas, DDS
Professor
The University of Iowa
Iowa City, Iowa

REFERENCES

1. Ziahosseini P, Hussain F, Millar BJ. Management of gingival black triangles. *Br Dent J.* 2014;217(10):559-563.
2. Cunliffe J, Pretty I. Patients' ranking of interdental

"black triangles" against other common aesthetic problems. *Eur J Prosthodont Restor Dent.* 2009;17(4):177-181.

3. Singh VP, Uppoor AS, Nayak DG, Shah D. Black triangle dilemma and its management in esthetic dentistry. *Dent Res J.* 2013;10(3):296-301.

4. De Araujo EM Jr, Fortkamp S, Baratieri LN. Closure of diastema and gingival recontouring using direct adhesive restorations: a case report. *J Esthet Restor Dent.* 2009;21(4):229-240.

5. Prato GP, Rotundo R, Cortellini P, et al. Interdental papilla management: a review and classification of the therapeutic approaches. *Int J Periodontics Restorative Dent.* 2004;24(3):246-255.

6. Sharma AA, Park JH. Esthetic considerations in interdental papilla: remediation and regeneration. *J Esthet Restor Dent.* 2010;22(1):18-28.

Many Technologies, One Restoration

David Burt, DDS

ABSTRACT

The single tooth implant restoration has existed in dentistry for some time, but the increasingly advanced technologies and streamlined workflows now available in clinical practice have greatly enhanced the process. Improvements in efficiency, functionality, and esthetics show that the profession is advancing rapidly. This article covers the case of a restoration for a patient who benefited considerably from today's digital technologies.

Procedures for the replacement of a missing tooth have come a long way from the times of G.V. Black and even since the more recent past. It would be reasonable to state that 20% of all dental advancements occurred from the dawn of modern dentistry up to the mid 1980s and that the remaining 80% of emerging dental technologies available today have been instituted since the introduction of digital radiography around that time, with the pace of technological advancements continuing to accelerate. The partial denture or three-unit bridge fabricated in the traditional method of impressions using polyether or polyvinyl siloxane materials, counter models, and bite registrations, along with the 3- to 4-week turnaround by a laboratory of a porcelain-fused-to-metal prosthesis, have been

replaced by digital impressions and CAD/CAM design and milling of ceramics that have greater esthetics and strength. An added benefit has been the realization of a greatly reduced turnaround time of only 1 week, or even the same day if done chairside.^{1,2}

These changes, along with the now mainstream dental implant and laser technologies, have given the practitioner and patient another fixed prosthetic option that does not involve multiple teeth, scalpels, or sutures. The utilization of these and other digital solutions allows conservation of structure, tissue, and time while achieving esthetic, natural-looking results.

Case Study

The patient had broken tooth No. 8 off below

the gingival level and had an immediate placement of an implant with graft after extraction. The case was deemed to be a two-stage surgery, with the implant being buried to maximize integration. At the 3-month mark (Figure 1), the site was evaluated and found to be ready for the uncovering and restoration of the implant. Topical anesthetic was placed, and a CO₂ (10,600 nm) laser was used to first locate the implant cover screw and then carve or shape the gingival tissue for an optimal emergence profile (Figure 2). This approach, of tissue ablation rather than cutting, has shown itself to be dimensionally stable, with little change in healing and close adaptation to the healing abutment placed after scanning (Figure 3). The time savings are significant, and the procedure is conservative of soft and hard tissue compared with performing a full thickness flap with sutures after inserting a healing abutment.

The patient was then digitally scanned by imaging each arch, a bite registration, and finally the scan of the site, with a dedicated scan body, or flag, seated into the implant (Figure 4 through Figure 6). This process would allow the laboratory to not only see and create a virtual soft-tissue model of the

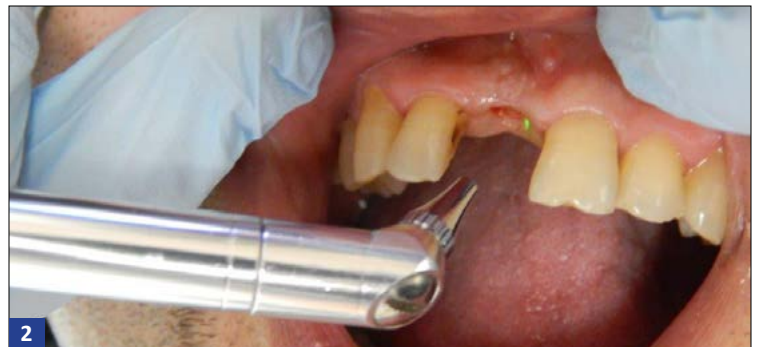
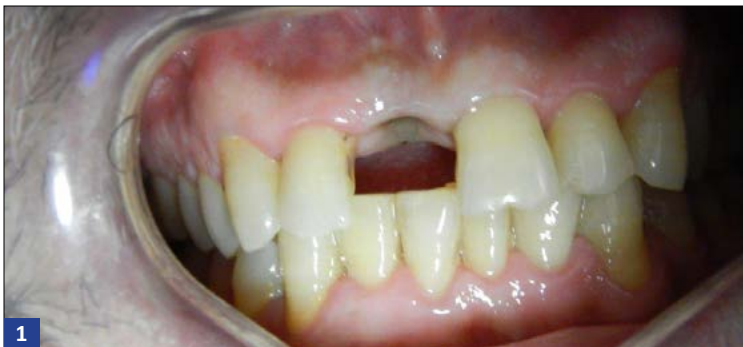
Fig 1. After 3 months, the site was ready for restoration of the implant. **Fig 2.** A CO₂ (10,600 nm) laser was used to first locate the implant cover screw and then shape the gingival tissue for an optimal emergence profile.

site, but also fix the position of the implant in the bone with the proper hex timing or internal geometry. The scan flags needed for any brand of implant are obtained either from the implant company or by asking the laboratory for a recommendation. Laboratory software, called libraries, for the flag orientation are critical for pouring or three-dimensional (3D) printing of the working model on which the abutment and crown will be designed and fabricated. Because the scans are digital, there is no distortion, as may be found in impression material or due to improper placement of a closed-tray impression coping back into the impression tray after removal from the mouth.

The case was emailed to the laboratory, and the digital creation commenced.

Custom abutments CAD-designed and milled out of titanium or zirconia are options, as well as stock Ti-base or UCLA abutments made for the implant brand. Abutment choices should be made by the practitioner based on the tissue depth, thickness, and biotype,³ as well as the potential emergence profile.

The ceramic crown, in this case a layered zirconia, was produced under the CAD/CAM principle using a 3D-printed model of the abutment seated on the implant (Figure 7). Porcelain was then stacked on the zirconia to give better translucency and esthetics, representing one of the few steps that was labor intensive and an analog process.

Delivery of the abutment and crown (Figure 8) was predictable because of the accuracy of digital impressions. The case was trial seated to determine basic fit, esthetics, and occlusion. The esthetics were presented to the patient, and he approved the final results. The abutment was torqued to recommended settings, and the crown was cemented using a long-term temporary cement (Figure 9 and Figure 10).

Conclusion

Although a single tooth implant restoration is not new to dentistry, cutting-edge technologies and workflows available to dentists today have led to exciting times in clinical practice. The degree of excellence that can be derived in efficiency, functionality, and esthetics shows that the profession is advancing rapidly, allowing dentists to practice in ways G.V. Black could have never imagined but would have heartily embraced.

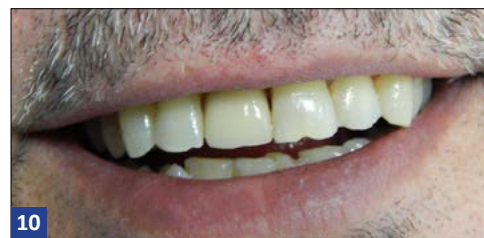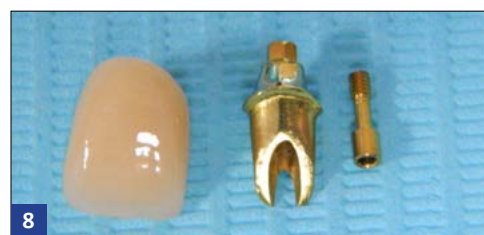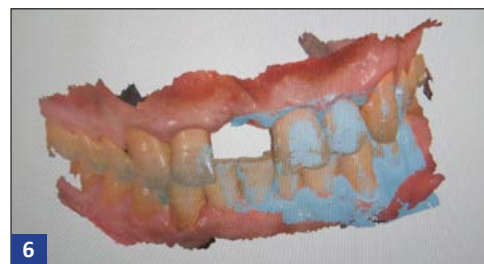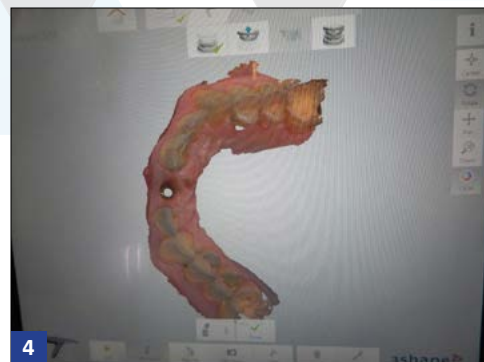
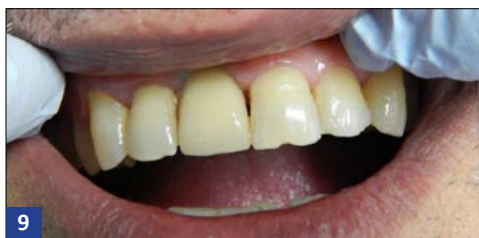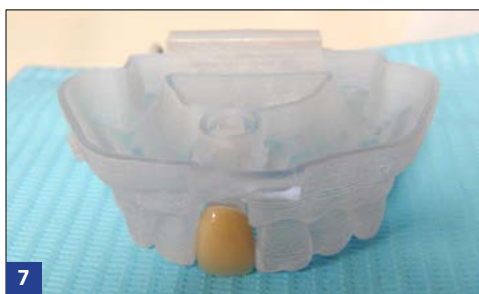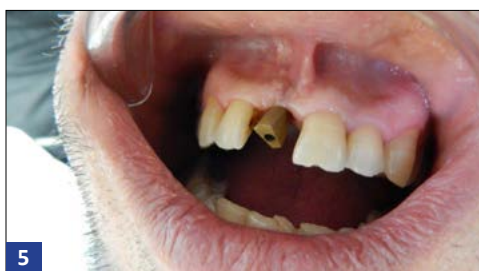


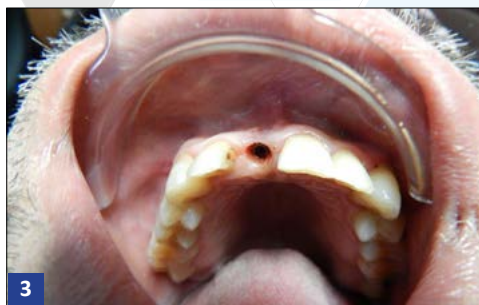Fig 3. The results of tissue ablation were shown to be dimensionally stable. **Fig 4.** The arches were scanned digitally. **Fig 5.** A scan body was seated into the implant. **Fig 6.** The bite registration was imaged. **Fig 7.** The layered zirconia ceramic crown was produced under the CAD/CAM principle using a 3D-printed model. **Fig 8.** The abutment and crown were predictable due to the accuracy of the digital impressions. **Fig 9.** The abutment was torqued to recommended settings. **Fig 10.** The crown was cemented using long-term temporary cement.

About the Author

David Burt, DDS
Private Practice
Allentown, Pennsylvania

Disclosure

The author had no disclosures to report.

References

1. Klim J, Corrales EB. Innovation in dentistry: CAD/

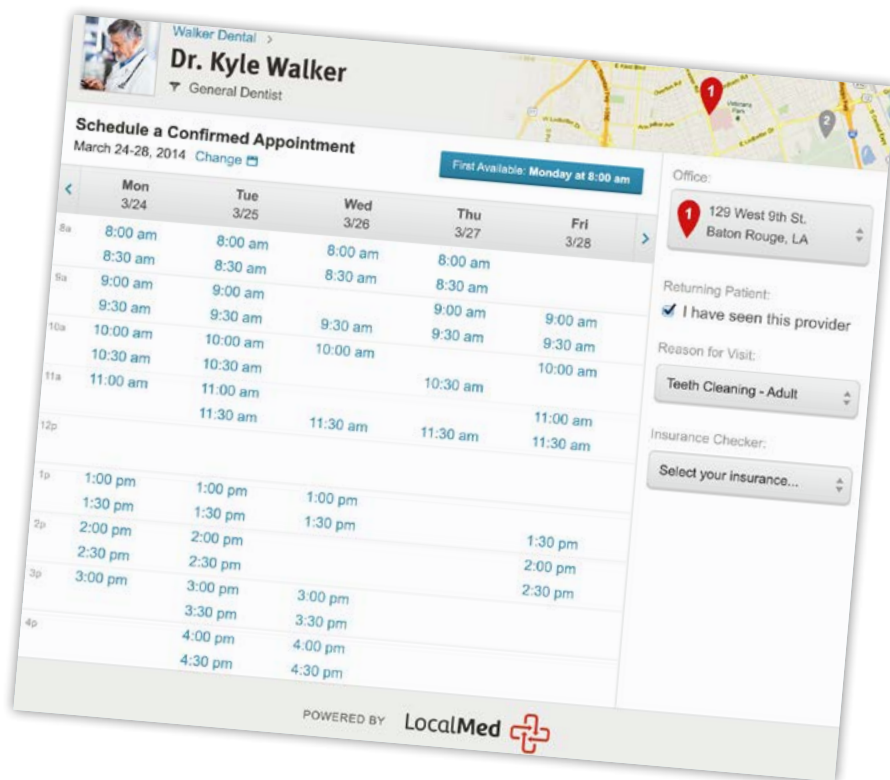
CAM restorative procedures. www.dentalacademyofce.com/courses//1996/pdf/1012cei_cad-cam_web.pdf. Published February 2009. Accessed July 14, 2017.

2. Birnbaum NS, Aaronson HB. Dental impressions using 3D digital scanners: virtual becomes reality. *Compend Contin Educ Dent*. 2008;29(8):494,496,498-505.
3. Lee A, Fu J-H, Wang H-L. Soft tissue biotype affects implant success. *Implant Dent*. 2011;20(3):e38-e47.



Can your patients schedule when it is convenient for them, or only when you are able to answer the phone? Are potential patients choosing other offices because you are not making it easy? Do you want to make scheduling easy for your patients, and fill up more of your chair time?

LOCALMED CAN HELP.



What is LocalMed?

LocalMed is the first online scheduling platform that allows patients to view accurate, real-time availabilities and book confirmed appointments, 24/7. In the same way you currently schedule, our system offers different time slots based on appointment types. You select which appointment types and chairs you want to make available; we take care of the rest.

How does it work?

By connecting with your existing practice management systems, we can read, display and fill your availabilities in real time. This is not a request system. Once an appointment is booked online by a patient, it is automatically uploaded into your schedule.

Bring patient convenience to your practice

While online scheduling is standard for just about every other industry, dental scheduling was often considered too complicated. But we thought, "Why can we book a flight across the country, but patients still can't schedule a routine exam or cleaning?"

The answer is that dental scheduling is like a jigsaw puzzle. Scheduling involves a complex series of steps that differ for every practice, and in many cases different plans for different days within the same practice. We saw this missing piece in the dental industry and we have spent the past three years building LocalMed to handle these complexities.

Putting it into perspective

More than 40 percent of appointments scheduled on our platform are made when the office is closed. This means those patients likely had no way to schedule during regular hours and, without an after-hours alternative, would likely have found another provider instead. The loss of just one new patient a month could cost the average practice more than \$10,000 a year in revenue.

Where do patients go to schedule?

The LocalMed "Schedule Online" widget brings real-time scheduling capabilities to multiple platforms. Adding our widget to your website and Facebook page makes it easy for patients to view your providers, compare availabilities, and book confirmed appointments. In addition, patients can schedule through localmed.com and several dental insurance directories on partner sites. Our goal is to bring real-time scheduling everywhere patients search, day or night.

No hidden fees, no long-term contract

We don't believe in locking our clients into long-term contracts, so we work to earn your business every month. We let our dentists try LocalMed free for the first month, and give them the option to cancel at any time. Our low monthly fee includes:

- Widget functionality on multiple websites, including your own
- Customizable provider profile on localmed.com and partner sites
- Staff training session
- Personal support representative

Bottom Line: We make scheduling easy for patients and more efficient for practices

A successful dental practice is not just about being a good dentist—it is also about running a business. Making it easier for your clients to schedule their appointments will help make your business more accessible and help increase your bottom line.

**Visit LocalMed.com/dentists,
or call (225) 590-3054 today to learn more.**